



**NATIONAL OPEN UNIVERSITY OF NIGERIA**

**SCHOOL OF SCIENCE AND TECHNOLOGY**

**COURSE CODE: CHS316**

**COURSE TITLE: Primary Eye Care**

Course Code	<b>CHS 316</b>
Course Title	<b>PRIMARY EYE CARE</b>
Course Developer	Kayode S. Olubiyi National Open University of Nigeria Lagos
Course Writer	Kayode S. Olubiyi National Open University of Nigeria Lagos
Programme Leader	Prof. Afolabi Adebajo School of Science and Technology National Open University of Nigeria Lagos
Course Coordinator	Kayode S. Olubiyi National Open University of Nigeria Lagos



**NATIONAL OPEN UNIVERSITY OF NIGERIA**

National Open University of Nigeria

Headquarters

14/16 Ahmadu Bello Way

Victoria Island

Lagos

Abuja Annex

245 Samuel Adesujo Ademulegun Street

Central Business District

Opposite Arewa Suites

Abuja

e-mail: [centralinfo@nou.edu.ng](mailto:centralinfo@nou.edu.ng)

URL: [www.nou.edu.ng](http://www.nou.edu.ng)

National Open University of Nigeria 2006

First Printed 2006

ISBN:

All Rights Reserved

Printed by .....

For

National Open University of Nigeria

# CHS 316: PRIMARY EYE CARE (2CU)

## COURSE GUIDE

<b>TABLE OF CONTENTS</b>	<b>PAGE</b>
Introduction.....	1
What you will learn in this course.....	1
Course Aim.....	1
Course Objectives.....	1-2
Working through this course.....	2-3
Course Materials.....	3
Study Units.....	3-4
Recommended Texts.....	4
Assignment File.....	4
Presentation schedule.....	4
Assessment.....	5
Tutor Marked Assignments (TMAs).....	5-6
Final Examination and Grading.....	6
Course Marking Scheme.....	7
Course Overview.....	7-8
How to get the most out of this course.....	8
Tutors and Tutorials.....	9

## **Introduction**

This course deals with the anatomy and physiology of the human eye, examines common ailments related to each of the component of the eyes, how an injured eye or any conditions related to the eye are treated and the effects of ageing on the eyes. The course aims to provide students with knowledge, attitude and specific skills involved in caring clients with eyes diseases and injuries.

Students are expected to nurse client in the specialized unit associate with eyes problem or diseases.

**NSS 305: Primary Eye Care** is a two credit course for students in the Bachelor of Science (Community Health) programme.

The course is broken to 4 modules with 10 study units. This course will introduce students to the anatomy and physiology of the human eye, examines common ailments related to each of the component of the eyes, how an injured eye or any conditions related to the eye are treated and the effects of ageing on the eyes. The course aims to provide students with knowledge, attitude and specific skills involved in caring clients with eyes diseases and injuries at all levels of health care.

Students are expected to nurse client in the specialized unit associate with eyes problem or diseases. At the end of the course, the learner is expected to demonstrate clear understanding of basic eye conditions.

This course guide provides you with what to expect in the course, how to work through the course material as a distance learner saddled with the responsibility of studying on your own and your overall responsibilities and expectations. Tutorial sessions are also linked up with the course to provide the needed support you required.

## **What You Will Learn In This Course**

Today, Nigeria has a growing population of 140 million people majority of who are in the rural areas. There is still a great imbalance in the provision of medical care facilities and it has become a great challenge to provide same for the larger population.

The overall aim of this course CHS 305: Primary Health Care aims at providing the learners with in depth understanding of eye defects and the need for proper understanding of this special sense organ whose major function is providing light to the entire body. It is hoped that learners will be better equipped to contribute to meaningful health living for all and sundries.

### **Course Objectives**

To achieve the aims set out above, the course sets the overall objective. In addition, each unit has specific objectives stated at the beginning of a unit. Learners are advised to read them carefully before going through the unit. You will have to refer to them during the course of your study to monitor your progress. You are encouraged to always refer to the Unit objectives after completing a Unit. This is the way you can be certain that you have done what was required of you in the unit.

The wider objectives of the course are set below. By meeting these objectives, you should have achieved the aims of the course as a whole.

On successful completion of the course, you should be able to:

- Understand the basic anatomy and physiology of the human eye
- Identify and explain common ailments related to the outer, middle and inner layer of the eyes.
- Understand common diseases and disorders of the Cornea
- Be able to answer some basic puzzles/questions in relation to eye.
- Discuss the effect of ageing on the Eye.

- Explain the Non-Penetrating and Penetrating Injuries/Wound of the Eye Ball
- Describe the general rules of Eye Care

### **Working through This Course**

To complete this course, you are required to study through the units, the recommended textbooks and other relevant materials. Each unit contains some self assessment exercises and tutor marked assignments and at some point in this course, you are required to submit the tutor marked assignments. This will be followed by an end of term examination.

### **Course Materials**

The following are the components of this course:

1. The course guide
2. Study Units
3. Textbooks
4. Assignment file
5. Presentation schedule

### **Study Units**

#### **STUDY UNITS**

Unit 1: Anatomy and physiology of the human eye

Unit 2: Common Ailments related to the outer layer of the eyes

Unit 3: Common Ailments related to the middle layer of the eyes

Unit 4: Common Ailments related to the inner layer of the eyes

Unit 5: Common diseases and disorders of the Corneal

Unit 6: Ophthalmic puzzles

Unit 7: Effect of Ageing on the Eye

Unit 8: Non-Penetrating Injuries/Wound of the Eye Ball

Unit 9: Penetrating Injuries/Wound of the Eye Ball

## **Recommended Textbooks for This Course**

Anatomy, Physiology & Pathology of the Human Eye Campbell and Reece, 2002, *Biology 6th edition*, ed. Benjamin Cummings, San Francisco.

## **Assignment File**

The assignment file will contain the Tutor Marked Assignment (TMA) which will constitute part of the continuous assessment (CA) of the course. There are 15 assignments in this course with each unit having an activity/exercise for you to do to facilitate your learning as an individual.

## **Presentation Schedule**

This presentation schedule in this course provides with important dates for completion of each tutor marked assignment. Please try to meet the deadlines.

## **Assessment**

There are two aspects to the assessment of the course. These are the Tutor marked assignment and written examination. In tackling the assignments, you are expected to apply information, knowledge and strategies gathered during the course. The assignments must be turned in to your tutor for formal assessment in accordance with the stated presentation schedules. The works you submit to your tutor for assessment will count for 30% of your total course work.

At the end of the course you will need to sit for a final written examination of three hour's duration. This examination will also count for 70% of your total course mark.

## **Tutor Marked Assignment (TMA)**

There Tutor-marked assignments in the each of the unit of this course. You are advised in your own interest to attempt and go through all the assignments at your own pleasure. You will be able to complete the assignments from the information and materials contained in your reading and study units. Those to be submitted for evaluation will be communicated to you through the Study Centre. There is other self activity contained in the instructional material to

facilitate your studies. Try to attempt it all. Feel free to consult any of the references to provide you with broader view and a deeper understanding of the course.

### **Final Examination and Grading**

The final examination of CHS 316 will be of 2 hours duration and have a value of 70% of the total course grade. The examination will consist of questions which have bearings with the attempted self assessment exercises and tutor marked assignments that you have previously encountered. Furthermore, all areas of the course will be evaluated. Make sure you give enough time to revise the entire course.

### **Course Marking Scheme**

The following table includes the course marking scheme

Table 1

<b>Assessment</b>	<b>Marks</b>
Assignment 1 – 10	10 assignments for the best 3 Total = 10% x 3 = 40%
Final examination	70% of overall course marks
Total	100% of course marks

### **Course Overview**

This table indicates the units, the number of weeks required to complete the assignments.

Unit	Title of Work	Week Activity	Assessment
	<b>Course Guide</b>	<b>Week 1</b>	
<b>Module 1</b>	<b>Introduction</b>		
Unit 1	Basic anatomy and physiology of the Eye	Week 2	

<b>Module 2</b>	<b>Common Ailments of the Eye</b>		
Unit 2	Common ailments of the Outer Eye	Week 3	
Unit 3	Common ailments of the Middle Eye	Week 4	
Unit 4	Common ailments of the Inner Eye	Week 5	
Unit 5	Common diseases and disorders of the Cornea	Week 6	
<b>Module 3</b>	<b>Changes in the Eye</b>		
Unit 6	Ophthalmic puzzles	Week 7	
Unit 7	Effects of Ageing on the Eye	Week 8	
<b>Module 4</b>	<b>Wound of the Eye and Basic Care</b>		
Unit 8	Non-penetrating wound of the Eye ball	Week 9	
Unit 9	Penetrating wound of the Eye ball	Week 10	

### **How to get the most out of the course**

In distance learning, the study units replace the university lecture. This is one of the greatest advantages of distance learning. You can read and work through specially designed study materials at your own pace and at time and place that suit you best. Think of it as reading the lecture notes instead of listening to a lecturer. In the same way that a lecturer might set you some reading task, the study units tell you when to read your other material. Just as a lecturer might give you an in-class exercise, your study units provide exercise for you to do at appropriate points.

**The following are practical strategies for working through the course:**

- Read the course guide thoroughly.
- Organize a study schedule.
- Stick to your own created study schedule.
- Read the introduction and objectives very well.
- Assemble your study materials.
- Work through the unit.
- Keep in mind that you will learn a lot by doing all your assignment carefully.
- Review the stated objectives.
- Don't proceed to the next unit until you are sure you have understood the previous unit.
- Keep to your schedules of studying and assignments.
- Review the course and prepare yourself for the final examination.

**Tutors and Tutorials**

There are 8 hours of effective tutorial provided in support of this course. Details will be communicated to you together with the name and phone number of your facilitator through the study centre.

Your tutor will mark and comment on your assignments, keep a close watch on your progress and any difficulties you might encounter and also provide assistance to you during the course. You must ensure that you submit your assignment as and at when due. You will get a feedback from your tutor as soon as possible to the assignments.

Do not hesitate to contact your tutor or study centre on phone or email in case of any of the following circumstances:

- You do not understand any part of the study units or the assigned reading
- You have difficulty with the self test or exercises.

- You have questions or problems with an assignment, tutors comments or grading of an assignment.

You are encouraged to attend the tutorials to allow for face to face contact with your tutor and ask questions which you needed answers immediately. It is also an opportunity to discuss any grey area with your tutor. You can equally prepare questions to the tutorial class for meaningful interactions. You are sure to gain a lot from actively participating in the discussion.

***Best of Luck.***

Course Code	<b>CHS 316</b>
Course Title	<b>PRIMARY EYE CARE</b>
Course Developer	Kayode S. Olubiyi National Open University of Nigeria Lagos
Course Writer	Kayode S. Olubiyi National Open University of Nigeria Lagos
Programme Leader	Prof. Afolabi Adebajo School of Science and Technology National Open University of Nigeria Lagos
Course Coordinator	Kayode S. Olubiyi National Open University of Nigeria Lagos



## **NATIONAL OPEN UNIVERSITY OF NIGERIA**

National Open University of Nigeria

Headquarters

14/16 Ahmadu Bello Way

Victoria Island

Lagos

Abuja Annex

245 Samuel Adesujo Ademulegun Street

Central Business District

Opposite Arewa Suites

Abuja

e-mail: [centralinfo@nou.edu.ng](mailto:centralinfo@nou.edu.ng)

URL: [www.nou.edu.ng](http://www.nou.edu.ng)

National Open University of Nigeria 2006

First Printed 2006

ISBN:

All Rights Reserved

Printed by .....

For  
National Open University of Nigeria

## **Unit 1 - ANATOMY AND PHYSIOLOGY OF THE HUMAN EYE**

1.0 Introduction

2.0 Objectives

3.0 Main Content

3.1 Anatomy and physiology of the human eye

3.2 The structures of the human eye

3.3 The physiology of the human eye

3.4 The Muscles of the human eye

3.5 The Physiology of sight

4.0 Conclusion

5.0 Summary

6.0 Tutor Marked Assignment

7.0 Reference

### **1.0 Introduction**

The eye is one of the special sense organ of the body for sight. It is the window of the body so says an adage. To this end, no one is expected to be careless in the care of his/her eyes. A proper understanding of the anatomy and physiology of this delicate structure which is the gateway to living is required by you.

This unit will present the anatomical structures of the eye as well as its physiological status. It is hoped that as a nurse, you will find it very instructive with a view to equip yourself with skills to provide eye care at all level.

## 2.0 Objectives

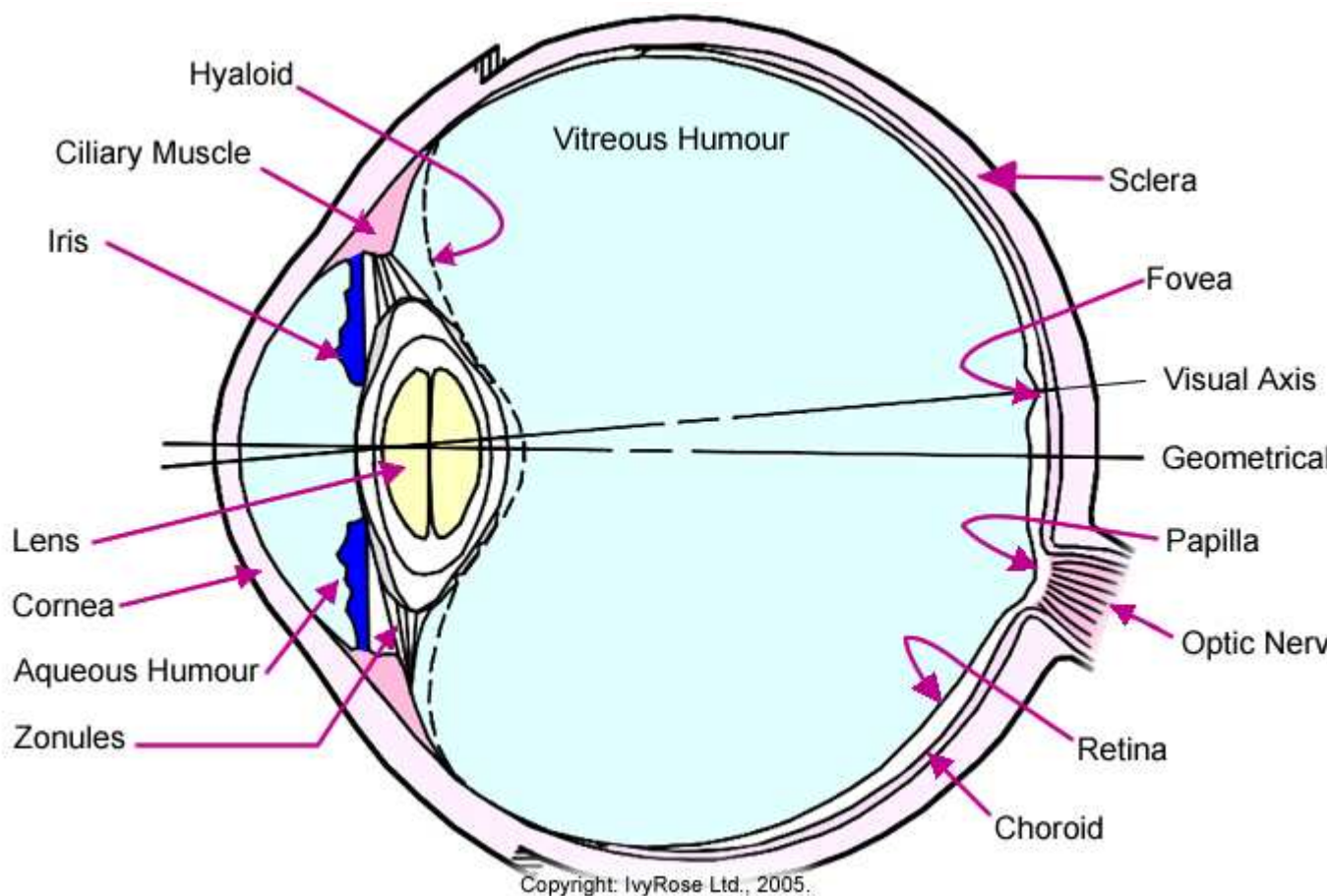
At the end of this unit, the learner will be able to:

- Draw and describe the structures of the human eye
- Explain the physiology of sight

## 3.0 Main Content

The human eye is a significant human sense organ. It allows humans conscious light perception, vision, which includes color differentiation and the perception of depth. The human eye has a 200° viewing angle and can see 10 million colors.

### 3.1 The Anatomy and physiology of the human eye



## **Fig. 1: Diagram of Human Eye**

### **3.2 The structures of the human eye**

The human eye is roughly spherical in shape. It is bounded by three distinct layers of tissue. The outer layer, the Sclera/sclerotic coat, is extremely tough. It is white in colour (the "white" of the eye) except in the front. Here it forms the transparent cornea, which admits light into the interior of the eye and bends the light rays so that they can be brought to a focus. The surface of the cornea is kept moist and dust-free by the secretion from the tear glands.

Like tissues of the central nervous system, the major metabolic fuel for the tissues of the eye is glucose. The cornea, which is not a homogenous tissue, obtains a relatively large percentage of its ATP from aerobic metabolism.

The middle coat of the eye, the choroid coat, is deeply pigmented with melanin and well supplied with blood vessels. It serves the very useful function of stopping the reflection of stray light rays within the eye. This is the same function that is accomplished by the dull black paint within a camera.

In the front of the eye, the choroid coat forms the iris. This may be pigmented and is responsible for the „color" of the eye. An opening, the pupil, is present in the center of the iris. The size of this opening is variable and under automatic control. In dim light (or times of danger) the pupil enlarges, letting more light into the eye. In bright light, the pupil closes down. This not only protects the interior of the eye from excessive illumination, but improves its image-forming ability and depth of field. Photographic enthusiasts, too, make a practice of "stopping down" the iris diaphragm of their cameras to the minimum permitted by the amount of light available in order to get the sharpest possible pictures. The inner coat of the eye is the retina. It contains the visual sensing apparatus (the actual light receptors, the rods and cones, and thus functions in the same way as the film of a camera). The exterior of the cornea is bathed by tears, while the interior is bathed by the aqueous humor. It is an is osmotic fluid containing

salts, albumin, globulin, glucose, and other constituents. The aqueous humor brings nutrients to the cornea and to the lens and removes end products of metabolism from these tissues. The vitreous humor is a collagenous or gelatinous-like mass that helps maintain the shape of the eye, but also allows it to retain some pliability.

There are no mitochondria in the outer segments of the rods and cones, however, where the visual pigments are located.

The lens of the eye is located just behind the iris. It is held in position by ligaments. Ordinarily, these are kept under tension and the lens is correspondingly flattened. However, contraction of muscles attached to these ligaments relaxes them and permits the lens to take on a more nearly spherical shape. These changes in lens shape enable the eye to shift its focus (accommodate) from far objects to near objects and vice versa.

The lens of the eye is bathed on one side by the aqueous humor and supported on the other side by the vitreous humor. The lens has no blood supply but it is an active metabolizing tissue. The lens is mostly water and protein. The proteins are synthesized within the lens, occurring mostly in an epithelial layer around the edge of the lens. The center area of the lens, the core, consists of the lens cells that were present at birth. The lens grows from the periphery. The human lens increases in weight and thickness with age and becomes less elastic. On average the lens may increase threefold in size and approximately 1.5-fold in thickness from birth to about age 80.

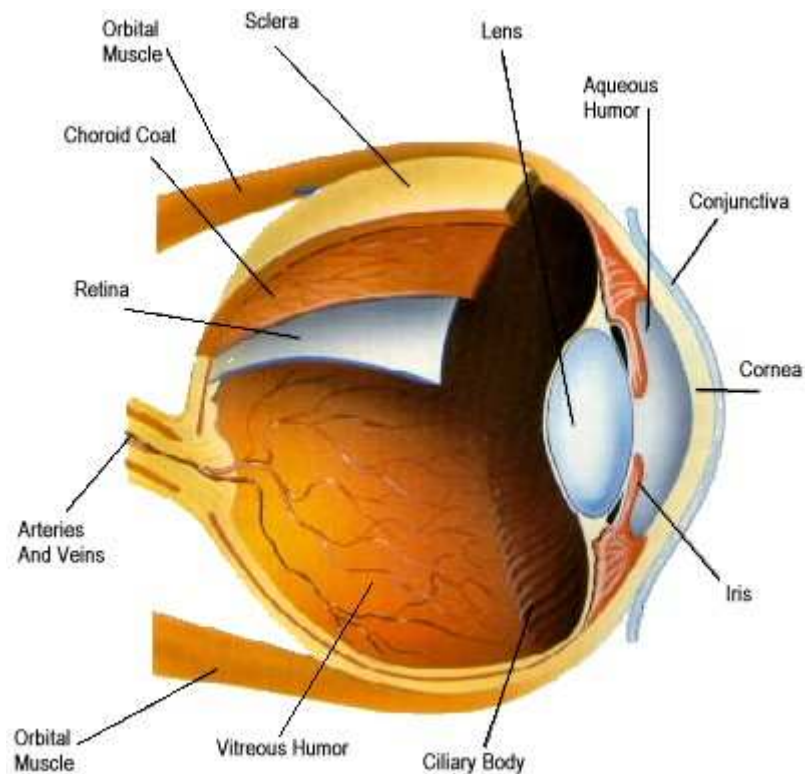
The proteins of the lens must be maintained in a native unaggregated state. These proteins are sensitive to various insults such as changes in the oxidation-reduction state of the cells, the osmolarity of the cells, excessively increased concentrations of metabolites, and various physical insults such as Ultra Violet irradiation.

The method of changing focus by changing the shape of the lens has no parallel in photography. Focus is changed in cameras by moving the position of the

entire lens with respect to the film. This method is also used in the eyes of some fishes, amphibians, snakes, and some mollusks. The iris and the lens divide the interior of the eyeball into two main chambers. The anterior one is filled with a watery fluid, the aqueous humor. The posterior chamber is filled with a jellylike material of marvelous clarity, the vitreous humor. Eyes are in continuous movement during watching.

Even, when they are observing a resting object they are doing small, involuntary movements. A view on retina is still changing, removing from the center of the yellow spot in flank and coming back to it. In the meantime the eye is trembling with large frequency. If a view on the retina were immobilize, it would turn pale and disappear, and later it would appear partial or whole.

Movement of the eyeball is accomplished by three pairs of muscles, the members of each pair working antagonistically. The coordinated action of these muscles enables the eyeball to be rotated in any direction. Thus we are able to train both eyes in a single direction. This produces two slightly differing views of the same scene which our brain is able to fuse into a single, three-dimensional image.



**Fig 2 : Eye movement in picture**

### **3.4 The physiology of human eye**

The workings of each of the parts are further summarized as follows:

- Aqueous Humour - The aqueous humour is a jelly-like substance located in the anterior chamber of the eye.
- Choroid - The choroid layer is located behind the retina and absorbs unused radiation
- Ciliary Muscle - The ciliary muscle is a ring-shaped muscle attached to the iris. It is important because contraction and relaxation of the ciliary muscle controls the shape of the lens
- Cornea - The cornea is a strong clear bulge located at the front of the eye (where it replaces the sclera - that forms the outside surface of the rest of the eye). The front surface of the adult cornea has a radius of approximately 8mm.

The cornea contributes to the image-forming process by refracting light entering the eye.

- Fovea - The fovea is a small depression (approx. 1.5 mm in diameter) in the retina.

This is the part of the retina in which high-resolution vision of fine detail is possible

- Hyaloid - The hyaloid diaphragm divides the aqueous humour from the vitreous humour.
- Iris - The iris is a diaphragm of variable size whose function is to adjust the size of the pupil to regulate the amount of light admitted into the eye. The iris is the coloured part of the eye (illustrated in blue above but in nature may be any of many shades of blue, green, brown, hazel, or grey)
- Lens - The lens of the eye is a flexible unit that consists of layers of tissue enclosed in a tough capsule. It is suspended from the ciliary muscles by the zonule fibers.
- Optic Nerve - The optic nerve is the second cranial nerve and is responsible for vision Each nerve contains approx. one million fibres transmitting information from the rod and cone cells of the retina.
- Papilla- The papilla is also known as the "blind spot" and is located at the position from which the optic nerve leaves the retina
- Pupil - The pupil is the aperture through which light - and hence the images we "see" and "perceive" - enters the eye. This is formed by the iris. As the size of the iris increases (or decreases) the size of the pupil decreases (or increases) correspondingly
- Retina - The retina may be described as the "screen" on which an image is formed by light that has passed into the eye via the cornea, aqueous humour, pupil, lens, then the hyaloid and finally the vitreous humour before reaching the retina.

The retina contains photosensitive elements (called rods and cones) that convert the light they detect into nerve impulses that are then sent onto the brain along the optic nerve

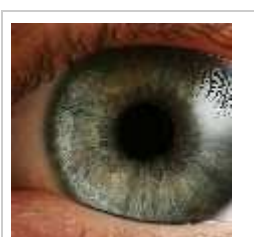


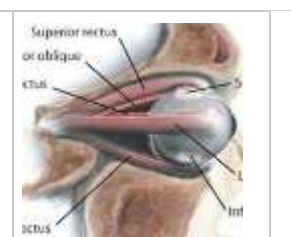
- Sclera - The sclera is a tough white sheath around the outside of the eye-ball.

This is the part of the eye that is referred to by the colloquial terms "white of the eye".

- Visual Axis- A simple definition of the "visual axis" is "a straight line that passes through both the centre of the pupil and the centre of the fovea".
- Vitreous Humour- The vitreous humour (also known as the "vitreous body") is a jelly-like substance.
- Zonules - The zonules (or "zonule fibers") attach the lens to the ciliary muscles

### 3.5 The Muscles of the human eye

Proper functioning of the eye requires six muscles that control movement. They work together to offer a wide field of vision, allowing for up, down, left and right movements. The eye is housed in the orbit of the skull with the six muscles holding it suspended in place.

			
<p><u>The Human Eye</u></p>	<p><u>The Muscles of the Eye</u></p>	<p><u>The Muscles of the Eye</u></p>	<p><u>The Muscles of the Eye</u></p>

### The Muscles of the Eye

For the human eye to function and move correctly, six muscles must work in unison to provide three-dimensional vision. The six muscles of the eye are:

- Superior rectus
- Medial rectus
- Lateral rectus
- Inferior rectus
- Superior oblique
- Inferior oblique

### **How the Eye Muscles Work**

The eye muscles work in pairs and movement of the eye muscle is often only a very small movement, a fraction of a degree. The muscles need to be coordinated for vision to be stereoscopic (three-dimensional vision). For example, if you look to the left, the lateral rectus muscle on the left side of your left eye contracts. At the same time, on the right side of the same eye, the medial rectus relaxes.

### **Which Muscles Control Which Movements**

- Lateral rectus and medial rectus control left and right movements
- Superior rectus and inferior rectus control up and down and medial movements
- Superior oblique and inferior oblique control up and down and outward movements

The four rectus muscles are attached at one end to a fibrous ring that encircles the optic nerve, and the other end of these muscles attaches to the sclera, midline, or widest part of the eyeball.

The superior oblique muscle attaches at one end to the optic foramen (the passage through the orbit of the eye), through the trochlea; a pulley-like

structure attached to the frontal bone (the upper part of each orbit) and the other end to the top part of the eyeball.

These muscles form a ‘cone’ within the orbit. The inferior oblique muscle, however, passes under the eye, near the floor of the orbit, and is attached to the eyeball (sclera) in between the superior rectus and lateral rectus.

### **Eyeball Motion**

Normal functioning means that both the eyes look in the same direction at the same time. When looking at an object, both eyes point to the object and the brain deciphers what it is. There are some muscular imbalances that cause the eyes to ‘vergence’ or ‘disconjugate’. This means the eyes move in opposite directions. The two types of vergence are:

1. convergence — both eyes moving nasally or inward (cross-eyed)
2. divergence — both eyes moving temporally or outward (wall-eyed)

This problem is known as strabismus (or heterotropia) and a person suffering from strabismus may experience double vision. Often one eye will look at an object and the other eye will point in the opposite direction. Usually, after a time, the brain learns to ignore the messages sent by the eye that is turned the wrong way, and interpret images from the ‘good’ eye.

Strabismus occurs in approximately 2% of children, or can be as a result of injury, paralysis or retinal disease. If the brain ignores the strabismic eye for a great length of time, this can result in amblyopia (dimness of sight) or ‘lazy eye’. Covering the ‘good’ eye and making the strabismic eye do all the work is how this condition is generally treated.

### **3.6 Physiology of Sight**

As light waves pass from the air into the eye, it moves sequentially through the cornea, aqueous humour, lens, and vitreous humour, and then it passes through the neural layer of the retina to the photoreceptors behind. The visual pigment in rods is rhodopsin. Rhodopsin forms and accumulates in the dark, as vitamin A

is oxidised to the 11-cis retinal form, and then combined with opsin to produce rhodopsin.

When rhodopsin absorbs light, it triggers a series of steps in which retinal changes shape from the 11-cis to the all-trans form, and releases opsin. Free opsin then acts enzymatically to catalyse the activation of the G protein transducin. In turn, transducin catalyses the activation of the enzyme phosphodiesterase, which hydrolyses cGMP to GMP, so removing it from the Na<sup>+</sup> channels, and consequently causing them to close. This prevents Na<sup>+</sup> from diffusing into the cell, resulting in hyperpolarisation, which in turn prevents neurotransmitter release at the cell's synapse with bipolar neurons.

Like rods, the visual pigments of cones are a combination of retinal and opsins, which associate and dissociate as part of a light dependent cycle. There are three different types of cone: blue, green and red. Each has a distinct type of opsin, and each responds to a different optimal wavelength, at which the opsin and retinal dissociate.

Overlap between their wavelength ranges, and stimulation of more than one cone type results in us perceiving intermediate colours such as yellow and purple. As in rods, light stimulated dissociation of retinal and opsin triggers the G protein mediated cascade of events that results in hyperpolarisation and light perception by the brain.

#### **4.0 Conclusion**

This unit has presented to you the anatomy and structures of the eye. In particular, the diagrammatic representation provided an opportunity to examine the workings of the eye with its attending muscles which allows us to move the eye at all directions. It hoped that you have tried your hands in drawing the diagram of the eye yourself. If not you are advised to do so.

#### **5.0 Summary**

The following are the high points of our discussion: the anatomy and physiology of the human eye, the structures of the human eye, the physiology of the human eye, the muscles of the human eye and the physiology of sight.

### **6.0 Tutor Marked Assignment**

Describe the six (6) muscles of the eye stating how it rotates

### **7.0 Resource and further reading**

Anatomy, Physiology & Pathology of the Human Eye Campbell and Reece, 2002, *Biology 6th edition*, ed. Benjamin Cummings, San Francisco.

## **UNIT 2: COMMON AILMENTS RELATED TO THE OUTER LAYER OF THE EYE**

1.0 Introduction

2.0 Objectives

3.0 Main Content

3.1 Outer parts of the Eye and their functions

3.2 Common Eye defects of the outer parts

3.2.1 Conjunctivitis

3.2.2 Corneal Ulcer

### 3.2.3 Dry Eye

4.0 Conclusion

5.0 Summary

6.0 Tutor Marked Assignment

7.0 References

## 1.0 Introduction

Having had a good understanding of the anatomy and physiology of the human eye particularly the structures, we will in this unit consider the different parts of the outer eye and the common eye defects.

## 2.0 Objectives

At the end of this unit, the learner will be able to:

- Identify the parts of the outer eye
- Highlight the common ailments of the outer eye
- Understand the management of the defects

## 3.0 Main Content

### 3.1 Outer part of the eye and its functions

#### Outer part

- Eyebrow which prevents the sweat from the forehead
- Eyelids which cover the eyes when not in use
- Eyelashes which catch dirt to prevent it from getting into the eyes

#### Visible part

- Cornea is the outer layer of an eye. It is thin and transparent.
- Iris lies behind the cornea and it is the coloured part of the eye

- Pupil controls the amount of light that enters the eye. It is black and round.
- Aqueous humor is a thick liquid that nourishes the bloodless, transparent cornea and the lens

### **Inner part**

- Vitreous humor is a thick substance between the lens and the retina
- Retina is the innermost layer of the eyeball situated behind the vitreous humor.
- Optic nerve is the nerve cells that joins at the back of the retina. It sends message to the brain.

### **3.1.2 Common eye defect**

- Nearsightedness: In nearsightedness, there is long eyeball with concave lenses near object clear but far object blurred.
- Farsightedness: There is short eyeball, convex lenses and near object not seen but far object clear.
- Astigmatism: There is abnormal corneas with clear but eyestrain and headaches
- Strabismus: There is cross-eye and wall-eye. Eye exercise by pediatrician needed to correct defect.
- Colourblindness: There is difficult in distinguishing colours
- Stye: This is an infection with fever, swelling and Inflammation
- Conjunctivitis: There is pink eye, crusty eyelids, pain swelling, very itchy and water discharge.

### **3.1.3 How to Diagnose Eye Infections**

#### **Instructions**

- Step 1: Look for signs of conjunctivitis, more commonly known as pink eye. Symptoms include irritation, redness of the eye, tearing or yellowish discharge. Pink eye is extremely contagious.
- Step 2: Observe signs of a sty, which is a small bump on the eyelid. Symptoms include tenderness and redness around the bump, discomfort, light sensitivity and tearing.
- Step 3: Watch for corneal inflammation. This could be keratitis and can occur with adults, as well as children. Keratitis does not usually affect a healthy eye, but it can occur if there is a scratch on the eye or if the eye is very dry. Symptoms include pain, swelling of the eyelid, blurred vision, redness and light sensitivity.
- Step 4: Detect whether you have dry eyes by looking for certain symptoms. These symptoms may include itching, a burning sensation, irritation, excessive tearing or blurred vision. Dry eyes are caused by environmental conditions, cigarette smoke, contact lenses or reading for an extended period of time.
- Step 5: Spot symptoms such as itching, swelling and irritation of the eyelids. These are common symptoms of blepharitis. Blepharitis is eyelid inflammation that can be chronic. Staphylococcus and seborrheic are the two types of the illness. Staphylococcus blepharitis starts during childhood and is caused by bacteria. Seborrheic blepharitis is caused by abnormal tear film.
- Step 6: Examine few cases of the outer eye namely:conjunctivitis,corneal ulcer and dry eye (Cicatria)

### **3.2.1 How to Identify Conjunctivitis**

#### **Instructions**

- Step 1: Observe whether there is redness of the eye. The eye takes on a bloodshot appearance at first. This is usually the most notable symptom of conjunctivitis.
- Step 2: Notice if there is watering of the eye. Pinkeye usually begins in one eye then quickly spreads to the other. Along with redness watering of the eye is one of the initial symptoms.
- Step 3: Notice if there is itching of the eye. People who are affected with conjunctivitis often rub the eye due to the itching that occurs. Frequent rubbing of the eye only increases the redness, makes the eye sore and may cause the infection to spread to the other eye through touching with unwashed hands.
- Step 4: Observe whether there is pain in the eye. Pain sometimes occurs with conjunctivitis. The pain may be most noticeable on blinking or moving the eye up, down or to the side. It may also feel as if something is in the eye, especially when blinking.
- Step 5: Notice the affect on your vision. People affected by conjunctivitis often experience blurred vision and/or the inability to focus properly with the affected eye.
- Step 6: Notice whether there is a pus-like discharge present. The discharge that occurs with pinkeye may be thick or stringy. As it dries it forms a crust that can cause the eyelids to stick together. This often occurs at night while sleeping. On awakening in the morning the person may find their eyelids stuck together and must moisten them with a warm cloth to remove the crusty residue.
- Step 7: Notice whether a sore throat or cold-like symptoms are present. These symptoms may occur with forms of conjunctivitis that are caused by a viral or bacterial infection. Conjunctivitis that is caused by allergies or irritation usually clears up on its own within a few days. If you

experience any symptoms of conjunctivitis you should see a physician for proper diagnosis and treatment

### **3.2.2 Treatment of Conjunctivitis**

We have all felt the uncomfortable feeling in the eyes; It is also called the “*pink eye or Apollo*”, a magic word that meant your not going to school for a couple of days. In ophthalmic practice it is called conjunctivitis.

### **3.2.3 What Are the Causes of Pinkeye?**

#### **Viral Infection**

Viruses that cause pinkeye are usually associated with accompanying cold or flu-like symptoms. The main difference between viral and bacterial conjunctivitis is the discharge. Viral infections are normally clear and watery while bacterial infections have a thick green or yellow mucus excretion. Viral pinkeye infections may also be accompanied by sinusitis symptoms and swollen eyelids.

#### **Bacterial Infections**

There are three main sources of bacterial pinkeye: staphylococci, pneumococci and streptococci. Bacterial infections are the cause of the crusty discharge patients experience during sleep.

#### **Chlamydia and Gonorrhea**

If a mother is infected with Chlamydia or gonorrhea, her baby may be born with Chlamydia or gonococcal pinkeye. In these cases, antibiotic treatment should begin immediately. Pinkeye can also be sexually transmitted.

#### **Allergic Reactions**

Allergic reactions can cause the tearing, redness and swelling associated with allergic conjunctivitis. Pollen, dust, mold and animal dander lead to inflammation of the conjunctiva in allergy patients.

### **Irritants**

Irritants such as cigarette smoke, aerosols, household cleaners and industrial waste products can cause the redness, swelling and itchiness associated with pinkeye. The eye should be washed out with water to remove the chemicals or other irritants.

### **Disease**

Chronic diseases can lead to pinkeye symptoms. Chronic cases of pinkeye can be a symptom of an undiagnosed disease. Autoimmune disorders such as rheumatoid arthritis and systemic lupus bring out the symptoms of pinkeye. Conjunctivitis has also been associated with diseases common in children, such as Kawasaki's disease, colitis and Crohn's disease.

#### **3.2.4 Requirements for face washing**

- Washcloth
- Bowl
- Hot water
- Sterile cotton balls
- Baby shampoo
- Antihistamine
- Prescribed antibiotic ointment
- Step 1: Wash the red away from the eye. A warm compress applied to the eyes for 5 to 10 minutes three or four times a day will make the patient feel better.
- Step 2: Keep the affected eyes clean. A lot of times conjunctivitis gets better all by itself, but to help the healing process along, keep the eyes

and eyelids clean by using a cotton ball dipped in clean or sterile water to wipe the crusts away.

- Step 3: Bath the eyes. A warm compress works well for children, but sometimes adults need a little something more. Adults who have a lot of discharge should make a solution of 1 part baby shampoo to 10 parts warm water. Dip a sterile cotton ball into the solution and use it to clean off your eyelashes, this works well.
- Step 4: Don't chlorinate the eyes. The chlorine in swimming pools can cause conjunctivitis, but without the chlorine, bacteria would grow and this could cause pinkeye too. Advise those who goes swimming in a chlorinated pool that they are susceptible to conjunctivitis. They should wear tight fitting goggles while in the water.

**Precautions:**

- If after five days the infection is getting worse, not better, refer the patient to the Eye Clinic
- If you come across a patient with red eye and significant eye pain, change in vision, or a copious amount of yellow or greenish discharge, immediately refer him/her to the Eye Clinic.

**3.3 Corneal ulcers**

Eyes are under major threat and are possibly the most taken for granted part of our body. Amongst the most serious eye diseases is corneal ulcer. It may lead to complete blindness and is also life threatening. In this condition the cornea, which is the transparent layer of the outer eye, gets infected. It is also called as eyesore or ulcerative keratitis.

In corneal ulcer, the epithelial layer of the cornea is disrupted. The cornea is responsible for refraction of the light that is received by the eyes. The transparent layer cornea carries pressure points as well as pain receptor.

Therefore development of corneal ulcers is extremely painful and unbearable. The eye may show aqueous flare and redness of the eye. Since the pain receptors are stimulated, there occurs release of substances like acetylcholine, histamine and prostaglandin.

The ulcer can be clearly seen under a Slit lamp. Schirmer's test is also performed in order to check for any other acute possibility. Rose Bengal dye and fluorescein dye are also used to do checks on corneal ulcer. Fluorescein stain is used to understand the spread of the ulcer.

The body does try to heal the ulcers. This is done in two ways. One is to introduce more blood vessels from the conjunctiva region. The second is to cause migration of the nearby epithelial cells. This is preceded by mitosis. If this is done successfully, the ulcer is healed by the fourth day. There are various types of corneal ulcers. These include superficial and deep corneal ulcers, Refractory corneal ulcers and melting ulcers. Although corneal ulcers are a common eye disease still, they have been avoided if proper eye care is done. Eating of balanced diet which includes lots of fresh green vegetables provide vitamin A and C which help in strengthening eyes. Since it is difficult to eat balanced diet everyday supplementation must be made an essential of the daily regime.

### **Dry Eyes**

Dry eye is a common ailment that can occur after refractive surgery. You of course knows that tears run from your eyes when you cry or when your eyes are irritated. But tears have a much more important everyday function. A film of tears, spread over the eye by a blink, makes the surface of the eye smooth and optically clear. Without our tear film, good vision would not be possible.

### ***1. The Outer Oily Layer***

There are three layers in the thin film of tears which coat the surface of the eye, an oily layer, a watery layer, and a layer of mucus. The outermost layer of the tear film is produced by small gland at the edge of the eyelid, called meibomian glands. The main purpose of this oily layer is to smooth the tear surface and reduce evaporation of tears.

### ***2. The Middle Watery Layer***

The middle layer, and largest of the three, makes up most of what we ordinarily think of as tears. This watery layer is produced by small glands scattered through the conjunctiva, which is the delicate membrane lining the inside of the eyelid and covering the eyeball, and by the major tear gland called the large lacrimal gland. This layer cleanses the eye and washes away foreign particles or irritants.

### ***3. The Inner Mucus Layer***

The innermost layer consists of mucus produced by other cells in the conjunctiva. This layer allows the watery layer to spread evenly over the surface of the eye and helps the eye to remain wet. Without mucus, tears would not adhere to the eye.

### ***What are the Different Kinds of Tears?***

There are at least two kinds of tear: those that lubricate the eye and those that are produced as a “reaction” to irritation or emotion. Tears, which lubricate the eye, are produced around the clock. Excessive tears occur when a foreign body irritates the eye or when a person experiences extremes of emotion, as in crying.

### ***What is Dry Eye?***

Dry eye occurs when the eye cannot produce enough tears to keep the eye wet and comfortable. Stinging, burning, scratchiness, stringy mucus, and excess irritation from smoke are usual symptoms. Problem with contact lenses can be caused by dry eyes and make it impossible to wear contact

lenses at all. Surprisingly, increased tearing may be a symptom of dry eyes. If the basic tear secretion is below normal, excess tears are produced by the lacrimal gland in response to irritation. Even though the eye is basically dry, overflow tearing can occur, masking the dryness, which caused them in the first place.

### **What Causes Dry Eye?**

Normally, tear production decreases with age. Dry eyes are more common in women, especially after the age of menopause, but can occur at any age in both men and women. Dry eye can also be associated with arthritis. In addition, the inside of the mouth may become dry due to inadequate production of saliva. Swallowing or eating food then becomes difficult. Patient with dry eyes, dry mouth, and arthritis are said to have Sjogren's syndrome.

Drugs and medication can also cause dry eyes by reducing tear secretion. Since these medications are often necessary, the dry eye condition may have to be tolerated or treated with "artificial tears." For a listing of drugs that can cause dry eyes, please refer to the last section of this brochure.

### **How is Dry Eye Diagnosed?**

Often an eye care professional is able to diagnose dry eyes by simply examining the eyes. Sometimes tests, which measure tear production, may be necessary. One widely used test involves the placement of filter paper strips under the lower eyelids to measure the rate of tear production under various conditions.

### **What is the Treatment for Dry Eye?**

The basis of treatment is replacement with artificial tears. Artificial tears are available without a prescription and are used as eye drops to lubricate the eyes and replace the missing moisture. There are many brands of artificial tears on the market, may be used as often as necessary, only once or twice a day, or as often as several times an hour. Solid inserts that

gradually release lubricants during the day are also beneficial to some patients.

Conserving the tears, which are naturally produced, is another approach to keeping the eye moist. Tears leave the eye through tear ducts in both eyelids and go down into the nose. These channels may be closed by your eye care professional to create a blockage which will keep the eyes moist for longer periods of time.

Preventing the evaporation of tears can also prove helpful. In winter, when the heat is turned on, a humidifier or a pan of water on the radiator may help add moisture to the air. Wrap-around glasses (illegal to wear while driving in some states) may cut down evaporation of eye moisture due to wind.

Anything that adds to dryness such as an overly warm room, hair dryers, windy days, or anything that adds an irritant to the air will make a person with dry eyes more uncomfortable. Smoking is especially bothersome. Scratchiness that is bothersome on first opening the eyes in the morning can be treated by using an ointment at bedtime. This can cause temporary blurring of vision, so many people use the least amount necessary to provide relief. Ointments containing Vitamin A are currently under investigation as treatment for dry eye, and early results are encouraging.

### **Who Can Treat Dry Eye?**

Please note that extreme dryness can cause serious damage to the eye. An examination and diagnosis by the eye specialists: ophthalmologists and ophthalmic nurse will provide the needed care for a dry eye.

### **3.5. What Drugs Can Cause Dry Eye?**

The following drugs may cause dry eye. Brand names may be different from the generic or clinical names listed below:

Acetophenazine	Diethazine	Methyldopa	Propranolol
Amitriptyline	Dimethendene	Methylthiouracil	Protriptyline
Antazoline	Diphenhydramine	Metoprolol	Pyrilamine
Atropine	Diphenylpyraline	Morphine	Scopolamine
Azatadine	Doxylamine	NitrousOxide	Tetrahydrocannabinol
Belladonna	Ether	Nortriptyline	THC
BetaBlockers	Ethopropazine	Opium	Thiethylperazine
Bromphreniramine	Fluphenazine	Oxprenolol	Thiopropazine
Carbinoxamine	Hashish	Perazine	Thiordazine
Carphenazine	Hexamethonium	Periciazizne	Thirporpazate
Chlorisondamine	Homatropine	Perphenazine	Trichloroethylene
Chlorpheniramine	Imipramine	Pheniramine	Trifluoperazine
Chlorpromazine	Isoretinoin	Piperacetazine	Trifupromazine
Clemastine	Marijuana	Practolol	Trimeprazine
Cyroheptadine	Mesoridazine	Prochlorperazine	Tripelennamine
Desipramine	Methdilazine	Promazine	Tripolidine
Dexbrompheniramine	Methotrimeprazine	Promethazine	
Dexchlorpheniramine	Metscopolamine	Propiomazine	

#### 4.0 Conclusion

We have examined some of the ailments that may occur in the eye. You are enjoined to go through it again and get the needed information that will assist you in the care of patients with common ailment and thereafter refer to the eye care specialists as the need arises.

#### 5.0 Summary

This unit has considered the topic common ailments affecting the components of the eye. This include pink eye, conjunctivitis, corneal ulcer, sty and dry eye. We shall take on other common ailments in the next unit.

### **6.0 Tutor Marked Assignment**

Describe the signs and symptoms of conjunctivitis. What will be your immediate care for your neighbour who show signs of conjunctivitis

### **7.0 References and Further Readings**

Anatomy, Physiology & Pathology of the Human Eye Campbell and Reece, 2002, *Biology 6th edition*, ed. Benjamin Cummings, San Francisco.

## **UNIT 3 - COMMON AILMENTS RELATED TO THE MIDDLE LAYER OF THE EYE**

1.0 Introduction

2.0 Objectives

3.0 Main Content

3.1 Overview of the Middle layer

3.2 Common ailments of the middle layer

4.0 Conclusion

5.0 Summary

6.0 Tutor Marked Assignment

7.0 Reference

## **1.0 Introduction**

We have just touched on few common ailments relating to the outer layer of the eye. In this unit we shall examine an overview of the middle layer and then consider common ailments relating to it. It is hoped you will follow systematically to grasp the required information to make you a provider of eye care in your domain.

## **2.0 Objectives**

At the end of this unit, the learner will be able to:

- Describe an overview of the middle layer
- Identify common ailments of the middle layer
- Understand the methods of treating the ailments

## **3.0 Main Content**

### **3.1 Overview of the Middle Layer of the Eye**

The middle layer of the eye-wall is the choroid. It consists of many blood vessels. They transfer the nutrients to the right place and regulate the temperature. The choroid first enters the corpus ciliary and then the iris.

The iris determines the colour of the eyes. It can be compared to the diaphragm of a camera. In the centre of the iris is an opening: the pupil. Orbicular muscles make the opening wider or smaller. When there is much light, the pupil

becomes more narrow. At twilight or darkness the pupil widens. So the pupil is an opening, although it seems to be black. That colour exists because the eye doesn't reflect the light that enters.

Behind the iris is the lens. It is kept at its place by very small fibers. The lens surely is transparent. It has the shape of a globoid. The inner eye muscles can change the globoid of the lens and that way sharpen the incoming image. Iris and lens divide the eye into the foremost and the rear chamber of the eye.

### **3.2. Common ailments of the middle layer**

#### **3.2.1 Amblyopia**

Amblyopia is poor vision in an eye that did not develop normal sight during early childhood. It is sometimes called "lazy eye." When one eye develops good vision while the other does not, the eye with poorer vision is called amblyopic. Usually, only one eye is affected by amblyopia, but it is possible for both eyes to be "lazy."

The condition is common, affecting approximately two or three out of every 100 people. The best time to correct amblyopia is during infancy or early childhood.

#### **What causes amblyopia?**

Amblyopia is caused by any condition that affects normal use of the eyes and visual development. In many cases, the conditions associated with amblyopia may be inherited.

Amblyopia has three major causes:

#### **Strabismus (misaligned eyes)**

Amblyopia occurs most commonly with misaligned or crossed eyes. The crossed eye "turns off" to avoid double vision, and the child uses only the better eye. The misaligned eye then fails to develop good vision. Amblyopia occurs when one eye is out of focus because it is more nearsighted, farsighted or astigmatic than the other.

The unfocused (blurred) eye "turns off" and becomes amblyopic. The eyes can look normal, but one eye has poor vision. This is the most difficult type of amblyopia to detect since the child appears to have normal vision when both eyes are open.

Amblyopia also can occur in both eyes if both eyes are very blurred. This can happen when there is a high amount of nearsightedness, farsightedness or astigmatism. This is called bilateral refractive amblyopia.

### **Cloudiness in the Normally Clear Eye Tissues (Cataract)**

An eye disease such as a cataract (a clouding of the eye's naturally clear lens) may lead to amblyopia. Any factor that prevents a clear image from being focused inside the eye can lead to the development of amblyopia in a child. This is often the most severe form of amblyopia.

### **How is amblyopia diagnosed?**

It is not easy to recognize amblyopia. A child may not be aware of having one strong eye and one weak eye. Unless the child has a misaligned eye or other obvious abnormality, there is often no way for parents to tell that something is wrong.

Amblyopia is detected by finding a difference in vision between the two eyes or poor vision in both eyes. Since it is difficult to measure vision in young children, your ophthalmologist often estimates visual acuity by watching how well a baby follows objects with one eye when the other eye is covered.

Using a variety of tests, the ophthalmologist observes the reactions of the baby when one eye is covered. If one eye is amblyopic and the good eye is covered, the baby may attempt to look around the patch, try to pull it off, or cry.

Poor vision in one eye does not always mean that a child has amblyopia. Vision can often be improved by prescribing glasses for a child.

The Ophthalmologist will also carefully examine the interior of the eye to see if other eye diseases may be causing decreased vision.

These diseases include:

- Cataracts
- Inflammations
- Tumors
- Other disorders of the inner eye

### **How is amblyopia treated?**

1. To correct amblyopia, a child must be made to use the weak eye. This is usually done by patching or covering the strong eye, often for weeks or months.
2. Even after vision has been restored in the weak eye, part-time patching may be required over a period of years to maintain the improvement. Glasses may be prescribed to correct errors in focusing. If glasses alone do not improve vision, then patching is necessary.
3. Amblyopia also may be treated by blurring the vision in the good eye with special eye drops or lenses to force the child to use the amblyopic eye. Amblyopia is usually treated before surgery to correct misaligned eyes, and patching is often continued after surgery as well.
4. If the ophthalmologist finds a cataract or other abnormality, surgery may be required to correct the problem. An intraocular lens may be implanted. After surgery, glasses or contact lenses can be used to restore focusing while patching improves vision.
5. Amblyopia cannot usually be cured by treating the cause alone. The weaker eye must be made stronger in order to see normally. Prescribing glasses or performing surgery can correct the cause of amblyopia, but the ophthalmologist must also treat the amblyopia itself.

### **3.2.3 Astigmatism**

Astigmatism occurs when the front surface of your eye (cornea) or the lens inside the eye is slightly irregular in shape, resulting in vision being blurred at all distances. Astigmatism is not a disease, but is actually a vision condition

that is quite common.

### **Causes of astigmatism**

- When the front of your eye or the lens inside the eye is more oval than round, light does not focus properly on the back of your eye (retina).
- The causes of this irregular shape are unclear.
- In some cases, it may be hereditary or it may result from such factors as pressure of the eyelids on the cornea.

### **How common is astigmatism?**

Most people have some degree of astigmatism. However, only moderate to highly astigmatic eyes may need corrective lenses.

### **Signs/symptoms of astigmatism**

- People with severe astigmatism will usually have blurred or distorted vision.
- Those with mild astigmatism may experience headaches, eye strain, fatigue or blurred vision at certain distances.

### **How is astigmatism diagnosed?**

A comprehensive eye examination by the ophthalmologist and optometrist will include tests for astigmatism.

### **Can astigmatism be corrected?**

Yes. Almost all levels of astigmatism can be optically corrected with properly prescribed and fitted eyeglasses or contact lenses.

### **Does astigmatism get progressively worse?**

Yes. Astigmatism may increase slowly. Regular optometric care can, however, help to insure that proper vision is maintained.

### **How do astigmatism affect lifestyle?**

You may have to adjust to wearing eyeglasses or contact lenses if you do not

wear them now. Other than that, astigmatism probably will not significantly affect your lifestyle at all.

### **3.2.4 Cataract**

#### **What is a cataract?**

A cataract is a clouding of the normally clear lens of the eye. It can be compared to a window that is frosted or yellowed.

There are many misconceptions about cataract. Cataract is not:

- a film over the eye;
- caused by overusing the eyes;
- spread from one eye to the other;
- a cause of irreversible blindness.

Common symptoms of cataract include:

- a painless blurring of vision;
- glare, or light sensitivity;
- poor night vision;
- double vision in one eye;
- needing brighter light to read;
- fading or yellowing of colors.

The amount and pattern of cloudiness within the lens can vary. If the cloudiness is not near the center of the lens, you may not be aware that a cataract is present.

#### **Causes of Cataract**

The most common type of cataract is related to aging of the eye. Causes of cataract include:

- family history;
- medical problems, such as diabetes;
- injury to the eye;
- medications, especially steroids;
- long-term, unprotected exposure to sunlight;

- previous eye surgery;
- unknown factors.

### **How is a cataract detected?**

A thorough eye examination by the Ophthalmologist can detect the presence of a cataract, as well as any other conditions that may be causing blurred vision or other eye problems.

Problems with other parts of the eye (e.g, cornea, retina, optic nerve) can be responsible for vision loss and may prevent you from having much or any improvement in vision after cataract surgery. If improvement in your vision is unlikely, cataract removal may not be recommended. The Ophthalmologist can tell you how much visual improvement is likely.

### **How fast does a cataract develop?**

How quickly the cataract develops varies among individuals, and may even be different between the two eyes. Most age-related cataracts progress gradually over a period of years.

Other cataracts, especially in younger people and people with diabetes, may progress rapidly over a short time. It is not possible to predict exactly how fast cataracts will develop in any given person.

### **How is cataract treated?**

Surgery is the only way a cataract can be removed. However, if symptoms of cataract are not bothering you very much, surgery may not be needed.

Sometimes a simple change in your eyeglass prescription may be helpful.

There are no medications, dietary supplements or exercises that have been shown to prevent or cure cataracts.

Protection from excessive sunlight may help slow the progression of cataracts.

Sunglasses that screen out ultraviolet (UV) light rays or regular eyeglasses with

a clear, anti-UV coating offer this protection.

### **When should surgery be done?**

1. Surgery should be considered when cataracts cause enough loss of vision to interfere with your daily activities.
2. It is not true that cataracts need to be "ripe" before they can be removed, or that they need to be removed just because they are present.
3. Cataract surgery can be performed when visual needs require it.
4. Based on the symptoms, the patient and the ophthalmologist should decide together when surgery is appropriate.
5. Cataract surgery is a highly successful procedure. Improved vision is the result in over 95% of cases, unless there is a problem with the cornea, retina, optic nerve or other structures. It is important to understand that complications can occur during or after the surgery, some severe enough to limit vision.

**4.0 Conclusion** We have discussed astigmatism, strabismus, amblyopia and cataracts as common ailments of the middle layer of the eye. Cataract in particular is a common cause of decreased vision, particularly for the elderly, but they are treatable. The Ophthalmologist can tell whether cataract or some other problem is the cause of vision loss at any point and can help you decide if when cataract surgery is appropriate.

### **5.0 Summary**

This unit has examined the middle layer coat of the eye. It also considered the common ailments which includes astigmatism, strabismus, amblyopia and cataracts.

### **6.0 Tutor Marked Assignment**

What is Astigmatism? Describe the methods of diagnosing and management of

a patient with cloudy vision.

## **7.0 References and Further readings**

Anatomy, Physiology & Pathology of the Human Eye Campbell and Reece, 2002, *Biology 6th edition*, ed. Benjamin Cummings, San Francisco.

## **UNIT 4: COMMON AILMENTS AND DISORDERS OF THE INNER LAYER**

1.Introduction

2.Objectives

3.Main Content

3.1. Overview of the inner eye

3.2 Diabetic Retinopathy

3.4 Macular Oedema

3.4 Glaucoma

4. Conclusion

5. Summary

6. Tutor marked Assignment

7. References and Further readings

## **1.0 Introduction**

This unit will examine some common disorders and diseases of the inner layer of the eye. It is worth mentioning here that this is where real action of sight takes place. Some of the structures involved include retina, aqueous humor and macula. The diseases include: diabetic retinopathy, macular oedema and glaucoma.

## **2.0 Objectives**

At the end of this unit, the learner will be able to:

- Describe the stages of diabetic retinopathy and management
- Describe macula oedema and glaucoma
- Enumerate the expected roles of a non-eye care specialists in the care of these diseases

## **3.0 Main Content**

### **3.1 Overview of the Inner Eye**

The inner layer of the eye-wall is the retina. If you compare it again with a camera, the retina is the shield on which the images are projected. Millions of cells are on it, which are sensible to the light. Everything they sense, they transmit to the optic nerve.

The retina has got two types of cells. The rods are especially on the side of the retina. They are only sensitive to light and darkness. The cones are more in the

centre. They are more sensitive to colours. People have about one million rods and seven million cones.

Exactly behind the pupil is the most sensitive spot of the retina: the yellow spot. There are only cones. At that spot in the eye we can see the colours very well and the sight is quite clearly. From the rods and cones the nerve-fibres leave. They join at the end of the eye, in the big optic nerve. At that spot there aren't any rods or cones. There the retina is insensitive to light and darkness. That's why that spot is called the blind spot.

### **3.2 Diabetic Retinopathy**

Diabetic retinopathy is a complication of diabetes and a leading cause of blindness. It occurs when diabetes damages the tiny blood vessels inside the retina, the light-sensitive tissue at the back of the eye. A healthy retina is necessary for good vision. A person with diabetic retinopathy at first may notice no changes to his/her vision. But over time, diabetic retinopathy can get worse and cause vision loss. Diabetic retinopathy usually affects both eyes.

#### **Stages of diabetic retinopathy**

Diabetic retinopathy has four stages:

1. **Mild Nonproliferative Retinopathy.** At this earliest stage, microaneurysms occur. They are small areas of balloon-like swelling in the retina's tiny blood vessels.
2. **Moderate Nonproliferative Retinopathy.** As the disease progresses, some blood vessels that nourish the retina are blocked.
3. **Severe Nonproliferative Retinopathy.** Many more blood vessels are blocked, depriving several areas of the retina with their blood supply. These areas of the retina send signals to the body to grow new blood vessels for nourishment.
4. **Proliferative Retinopathy.** At this advanced stage, the signals sent by the retina for nourishment trigger the growth of new blood vessels. This

condition is called proliferative retinopathy. These new blood vessels are abnormal and fragile. They grow along the retina and along the surface of the clear, vitreous gel that fills the inside of the eye.

By themselves, these blood vessels do not cause symptoms or vision loss. However, they have thin, fragile walls. If they leak blood, severe vision loss and even blindness can result.

### **Who is at risk for diabetic retinopathy**

Let us now examine those who are at risk of diabetic retinopathy.

- All people with diabetes--both type 1 and type 2--are at risk. That's why everyone with diabetes should get a comprehensive dilated eye exam at least once a year.
- Between 40 to 45 percent of persons diagnosed with diabetes have some stage of diabetic retinopathy.
- During pregnancy, diabetic retinopathy may be a problem for women with diabetes. To protect vision, every pregnant woman with diabetes should have a comprehensive dilated eye exam as soon as possible.

### **How does diabetic retinopathy cause vision loss?**

Blood vessels damaged from diabetic retinopathy can cause vision loss in two ways:

1. Fragile, abnormal blood vessels can develop and leak blood into the center of the eye, blurring vision. This is **proliferative retinopathy** and is the fourth and most advanced stage of the disease.
2. Fluid can leak into the center of the macula, the part of the eye where sharp, straight-ahead vision occurs. The fluid makes the macula swell, blurring vision. This condition is called **macular edema**. It can occur at any stage of diabetic retinopathy, although it is more likely to occur as the disease progresses. About half of the people with proliferative retinopathy also have macular oedema.

## **Does diabetic retinopathy have any symptoms?**

You may wish to ask against all these background do diabetic retinopathy has no early warning signs? Please don't wait for signs and symptoms. Encourage your clients to have a comprehensive dilated eye exam at least once a year.

## **Diagnosis of macular oedema and diabetic retinopathy**

Macular oedema and diabetic retinopathy are detected during a comprehensive eye exam that includes:

- **Visual acuity test.** This eye chart test measures how well you see at various distances.
- **Dilated eye exam.** Drops are placed in your eyes to widen, or dilate, the pupils. Your eye care professional uses a special magnifying lens to examine your retina and optic nerve for signs of damage and other eye problems. After the exam, your close-up vision may remain blurred for several hours.
- **Tonometry.** An instrument measures the pressure inside the eye. Numbing drops may be applied to your eye for this test.

Eye care professional checks your retina for early signs of the disease, including:

- Leaking blood vessels.
- Retinal swelling (macular edema).
- Pale, fatty deposits on the retina--signs of leaking blood vessels.
- Damaged nerve tissue.
- Any changes to the blood vessels.

If your eye care professional believes you need treatment for macular edema, injected into your arm. Pictures are taken as the dye passes through the blood vessels in your retina. The test allows your eye care professional to identify any leaking blood vessels and recommend treatment.

### **Treatment of diabetic retinopathy treated**

During the first three stages of diabetic retinopathy, no treatment is needed, unless you have macular edema. To prevent progression of diabetic retinopathy, people with diabetes should control their levels of blood sugar, blood pressure, and blood cholesterol.

Proliferative retinopathy is treated with laser surgery. This procedure is called scatter laser treatment. Scatter laser treatment helps to shrink the abnormal blood vessels. The Eye doctor places 1,000 to 2,000 laser burns in the areas of the retina away from the macula, causing the abnormal blood vessels to shrink. Because a high number of laser burns are necessary, two or more sessions usually are required to complete treatment. Although the patient may notice some loss of your side vision, scatter laser treatment can save the rest of his/her sight. Scatter laser treatment may slightly reduce your color vision and night vision.

Scatter laser treatment works better before the fragile, new blood vessels have started to bleed. That is why it is important to have regular, comprehensive dilated eye exams. Even if bleeding has started, scatter laser treatment may still be possible, depending on the amount of bleeding.

If the bleeding is severe, there may be a need for a surgical procedure called a vitrectomy. During a vitrectomy, blood is removed from the center of the eye.

### **3.3 Treatment of macular edema**

Macular edema is treated with laser surgery. This procedure is called focal laser treatment. The Eye doctor places up to several hundred small laser burns in the areas of retinal leakage surrounding the macula. These burns slow the leakage of fluid and reduce the amount of fluid in the retina. The surgery is usually completed in one session. Further treatment may be needed.

A patient may need focal laser surgery more than once to control the leaking

fluid. If macular edema is observed in both eyes and require laser surgery, generally only one eye will be treated at a time, usually several weeks apart. Focal laser treatment stabilizes vision. In fact, focal laser treatment reduces the risk of vision loss by 50 percent. In a small number of cases, if vision is lost, it can be improved. Quickly refer such person to the eye care professional if there is vision loss.

### **3.4 Different Types of Glaucoma**

The two main types of glaucoma are open angle glaucoma, or primary open angle glaucoma (POAG), and angle closure glaucoma. Others are: Secondary Glaucoma, Normal Tension Glaucoma (NTG) and Pigmentary Glaucoma

#### **Primary Open Angle Glaucoma**

This is the most common form of glaucoma, affecting about three million Americans. It happens when the eye's drainage canals become clogged over time. The inner eye pressure (also called intraocular pressure or IOP) rises because the correct amount of fluid can't drain out of the eye. With open angle glaucoma, the entrances to the drainage canals are clear and should be working correctly. The clogging problem occurs inside the drainage canals, like the clogging that can occur inside the pipe below the drain in a sink.

Most people have no symptoms and no early warning signs. If open angle glaucoma is not diagnosed and treated, it can cause a gradual loss of vision. This type of glaucoma develops slowly and sometimes without noticeable sight loss for many years. It usually responds well to medication, especially if caught early and treated.

#### **Angle Closure Glaucoma**

This type of glaucoma is also known as acute glaucoma or narrow angle glaucoma. It is much more rare and is very different from open angle glaucoma in that the eye pressure usually goes up very fast. This happens when the

drainage canals get blocked or covered over, like the clog in a sink when something is covering the drain. With angle closure glaucoma, the iris and cornea is not as wide and open as it should be. The outer edge of the iris bunches up over the drainage canals, when the pupil enlarges too much or too quickly. This can happen when entering a dark room.

A simple test can be used to see if your angle is normal and wide or abnormal and narrow. Treatment of angle closure glaucoma usually involves surgery to remove a small portion of the outer edge of the iris. This helps unblock the drainage canals so that the extra fluid can drain. Usually surgery is successful and long lasting. However, you should still receive regular check-ups.

Symptoms of angle closure glaucoma may include headaches, eye pain, nausea, rainbows around lights at night, and very blurred vision.

### **Secondary Glaucoma**

Glaucoma can occur as the result of an eye injury, inflammation, tumor or in advanced cases of cataract or diabetes. It can also be caused by certain drugs such as steroids. This form of glaucoma may be mild or severe. The type of treatment will depend on whether it is open angle or angle closure glaucoma.

### **Normal Tension Glaucoma (NTG)**

Normal tension glaucoma is also known as low tension glaucoma or normal pressure glaucoma. In this type of glaucoma, the optic nerve is damaged even though intraocular pressure (IOP) is not very high. Doctors do not know why some people's optic nerves are damaged even though they have what is considered to be "normal" (between 12-22 mm Hg) pressure levels.

Those at higher risk for this form of glaucoma are people with a family history of normal tension glaucoma, people of Japanese ancestry, and people with a history of systemic heart disease, such as irregular heart rhythm. Normal tension glaucoma is usually detected after an examination of the optic nerve.

The Glaucoma Research Foundation sponsored an international study to help

determine the best treatment for this type of glaucoma (Collaborative NTG Study). The study concluded eye drops that lower IOP were effective even in cases of normal tension glaucoma. Currently, most doctors treat normal tension glaucoma by keeping normal eye pressures as low as possible with medicines, laser surgery, or filtering surgery

#### **4.0 Conclusion**

There is no doubt that your understanding of these disorders will go along way at helping you to contribute to preventing avoidable blindness in your domain and the country at large.

#### **5.0 Summary**

We have examined the common diseases and disorders of the inner layer of the eye. These include diabetic retinopathy, macula oedema and glaucoma.

#### **6.0 Tutor Marked Assignment**

1. List out the types of glaucoma and describe the stages of diabetic retinopathy

#### **7.0 References and Further readings**

Anatomy, Physiology & Pathology of the Human Eye Campbell and Reece, 2002, *Biology 6th edition*, ed. Benjamin Cummings, San Francisco.

### **Unit 5: COMMON DISEASES AND DISORDERS OF THE CORNEA**

- 1 Introduction
- 2 Objectives
- 3 Main Content
  - 3.1. The structures of Cornea
  - 3.2 Cornea responses to Injuries

### 3.3 Common diseases and disorders of Cornea

- 4 Conclusion
- 5 Summary
- 6 Tutor marked Assignment
- 7 References and Further readings

## **1.0 Introduction**

This unit is specially dedicated to discuss the common ailments of the cornea. The cornea is the eye's outermost layer. It is the clear, dome-shaped surface that covers the front of the eye. The colour and turgor of the cornea is what makes vision possible. We shall examine its structure , how it responds to injury as well as its diseases and disorders.

## **2.0 Objectives**

**At** the end of this unit, the learner will be able to:

- Clearly describe the structures of cornea
- Describe the common diseases and disorders of the cornea

## **3.0 Main Content**

### **3.1 Cornea Injuries, Diseases and Disorders**

Although the cornea is clear and seems to lack substance, it is actually a highly organized tissue. Unlike most tissues in the body, the cornea contains no blood vessels to nourish or protect it. Instead, it receives nourishment from the tears and aqueous humor that fills the chamber behind it. Because the cornea is so thin and delicate, it is very vulnerable to injury. Even the presence of even the tiniest blood vessels can interfere with its function.

must be free of any cloudy or opaque areas. The corneal tissue is arranged in five basic layers. These five layers are:

- **Epithelium**

The epithelium is the cornea's outermost region, comprising about 10 percent of the tissue's thickness. The epithelium functions primarily to: (1) Block the passage of foreign material, such as dust, water, and bacteria, into the eye and other layers of the cornea; and (2) Provide a smooth surface that absorbs oxygen and cell nutrients from tears, then distributes these nutrients to the rest of the cornea. The epithelium is filled with thousands of tiny nerve endings that make the cornea extremely sensitive to pain when rubbed or scratched. The part of the epithelium that serves as the foundation on which the epithelial cells anchor and organize themselves is called the basement membrane.

- **Bowman's Layer**

Lying directly below the basement membrane of the epithelium is a transparent sheet of tissue known as Bowman's layer. It is composed of strong layered protein fibers called collagen. Once injured, Bowman's layer can form a scar as it heals. If these scars are large and centrally located, some vision loss can occur.

- **Stroma**

Beneath Bowman's layer is the stroma, which comprises about 90 percent of the cornea's thickness. It consists primarily of water (78 percent) and collagen (16 percent), and does not contain any blood vessels. Collagen gives the cornea its strength, elasticity, and form. The collagen's unique shape, arrangement, and spacing are essential in producing the cornea's light-conducting transparency.

- **Descemet's Membrane**

Under the stroma is Descemet's membrane, a thin but strong sheet of tissue that serves as a protective barrier against infection and injuries. Descemet's membrane is composed of collagen fibers (different from those of the stroma) and is made by the endothelial cells that lie below it. Descemet's membrane is regenerated readily after injury.

- **Endothelium**

The endothelium is the extremely thin, innermost layer of the cornea. Endothelial cells are essential in keeping the cornea clear. Normally, fluid leaks slowly from inside the eye into the middle corneal layer (stroma). The endothelium's primary task is to pump this excess fluid out of the stroma. Without this pumping action, the stroma would swell with water, become hazy, and ultimately opaque. In a healthy eye, a perfect balance is maintained between the fluid moving into the cornea and fluid being pumped out of the cornea. Once endothelium cells are destroyed by disease or trauma, they are lost forever. If too many endothelial cells are destroyed, corneal edema and blindness ensue, with corneal transplantation the only available therapy.

### **3.2 Cornea response to injury**

The cornea copes very well with minor injuries or abrasions. If the highly sensitive cornea is scratched, healthy cells slide over quickly and patch the injury before infection occurs and vision is affected. If the scratch penetrates the cornea more deeply, however, the healing process will take longer, at times resulting in greater pain, blurred vision, tearing, redness, and extreme sensitivity to light. These symptoms require professional treatment. Deeper scratches can also cause corneal scarring, resulting in a haze on the cornea that can greatly impair vision. In this case, a corneal transplant may be needed.

What are some diseases and disorders affecting the cornea?

### **3.3 Common diseases and disorders of the cornea**

**Allergies.** Allergies affecting the eye are fairly common. The most common allergies are those related to pollen, particularly when the weather is warm and dry. Symptoms can include redness, itching, tearing, burning, stinging, and watery discharge, although they are not usually severe enough to require medical attention. Antihistamine decongestant eye drops can effectively reduce these symptoms, as does rain and cooler weather, which decreases the amount of pollen in the air. An increasing number of eye allergy cases are related to medications and contact lens wear. Also, animal hair and certain cosmetics,

such as mascara, face creams, and eyebrow pencil, can cause allergies that affect the eye. Touching or rubbing eyes after handling nail polish, soaps, or chemicals may cause an allergic reaction. Some people have sensitivity to lip gloss and eye makeup. Allergy symptoms are temporary and can be eliminated by not having contact with the offending cosmetic or detergent.

**Conjunctivitis (Pink Eye).** This term describes a group of diseases that cause swelling, itching, burning, and redness of the conjunctiva, the protective membrane that lines the eyelids and covers exposed areas of the sclera, or white of the eye. Conjunctivitis can spread from one person to another and affects large number of people at any given time. Conjunctivitis can be caused by a bacterial or viral infection, allergy, environmental irritants, a contact lens product, eye drops, or eye ointments. At its onset, conjunctivitis is usually painless and does not adversely affect vision. The infection will clear in most cases without requiring medical care. But for some forms of conjunctivitis, treatment will be needed. If treatment is delayed, the infection may worsen and cause corneal inflammation and a loss of vision.

**Corneal Infections.** Sometimes the cornea is damaged after a foreign object has penetrated the tissue, such as from a poke in the eye. At other times, bacteria or fungi from a contaminated contact lens can pass into the cornea. Situations like these can cause painful inflammation and corneal infections called keratitis. These infections can reduce visual clarity, produce corneal discharges, and perhaps erode the cornea. Corneal infections can also lead to corneal scarring, which can impair vision and may require a corneal transplant.

As a general rule, the deeper the corneal infection, the more severe the symptoms and complications. It should be noted that corneal infections, although relatively infrequent, are the most serious complication of contact lens wear.

Minor corneal infections are commonly treated with anti-bacterial eye drops. If the problem is severe, it may require more intensive antibiotic or anti-fungal treatment to eliminate the infection, as well as steroid eye drops to reduce inflammation. Frequent

visits to an eye care professional may be necessary for several months to eliminate the problem.

**Dry Eye.** The continuous production and drainage of tears is important to the eye's health. Tears keep the eye moist, help wounds heal, and protect against eye infection. In people with dry eye, the eye produces fewer or less quality tears and is unable to keep its surface lubricated and comfortable.

The tear film consists of three layers--an outer, oily (lipid) layer that keeps tears from evaporating too quickly and helps tears remain on the eye; a middle (aqueous) layer that nourishes the cornea and conjunctiva; and a bottom (mucin) layer that helps to spread the aqueous layer across the eye to ensure that the eye remains wet. As we age, the eyes usually produce fewer tears. Also, in some cases, the lipid and mucin layers produced by the eye are of such poor quality that tears cannot remain in the eye long enough to keep the eye sufficiently lubricated.

The main symptom of dry eye is usually a scratchy or sandy feeling as if something is in the eye. Other symptoms may include stinging or burning of the eye; episodes of excess tearing that follow periods of very dry sensation; a stringy discharge from the eye; and pain and redness of the eye. Sometimes people with dry eye experience heaviness of the eyelids or blurred, changing, or decreased vision, although loss of vision is uncommon. Dry eye is more common in women, especially after menopause. Surprisingly, some people with dry eye may have tears that run down their cheeks. This is because the eye may be producing less of the lipid and mucin layers of the tear film, which help keep tears in the eye. When this happens, tears do not stay in the eye long enough to thoroughly moisten it.

Dry eye can occur in climates with dry air, as well as with the use of some drugs, including antihistamines, nasal decongestants, tranquilizers, and anti-depressant drugs. People with dry eye should let their health care providers know all the medications they are taking, since some of them may intensify dry eye symptoms.

People with connective tissue diseases, such as rheumatoid arthritis, can also develop dry eye. It is important to note that dry eye is sometimes a symptom of Sjögren's syndrome, a disease that attacks the body's lubricating glands, such as the tear and salivary glands. A complete physical examination may diagnose any underlying diseases.

Artificial tears, which lubricate the eye, are the principal treatment for dry eye. Sterile ointments are sometimes used at night to help prevent the eye from drying. Using humidifiers, wearing wrap-around glasses when outside, and avoiding outside windy and dry conditions may bring relief. For people with severe cases of dry eye, temporary or permanent closure of the tear drain (small openings at the inner corner of the eyelids where tears drain from the eye) may be helpful.

**Fuchs' Dystrophy.** Fuchs' dystrophy is a slowly progressing disease that usually affects both eyes and is slightly more common in women than in men. Although doctors can often see early signs of Fuchs' dystrophy in people in their 30s and 40s, the disease rarely affects vision until people reach their 50s and 60s.

Fuchs' dystrophy occurs when endothelial cells gradually deteriorate without any apparent reason. As more endothelial cells are lost over the years, the endothelium becomes less efficient at pumping water out of the stroma. This causes the cornea to swell and distort vision. Eventually, the epithelium also takes on water, resulting in pain and severe visual impairment.

Epithelial swelling damages vision by changing the cornea's normal curvature, and causing a sight-impairing haze to appear in the tissue. Epithelial swelling will also produce tiny blisters on the corneal surface. When these blisters burst, they are extremely painful.

At first, a person with Fuchs' dystrophy will awaken with blurred vision that will gradually clear during the day. This occurs because the cornea is normally thicker in the morning; it retains fluids during sleep that evaporate in the tear film while we are awake. As the disease worsens, this swelling will remain constant and reduce vision throughout

the day.

When treating the disease, doctors will try first to reduce the swelling with drops, ointments, or soft contact lenses. They also may instruct a person to use a hair dryer, held at arm's length or directed across the face, to dry out the epithelial blisters. This can be done two or three times a day.

When the disease interferes with daily activities, a person may need to consider having a corneal transplant to restore sight. The short-term success rate of corneal transplantation is quite good for people with Fuchs' dystrophy. However, some studies suggest that the long-term survival of the new cornea can be a problem.

**Herpes Zoster (Shingles).** This infection is produced by the varicella-zoster virus, the same virus that causes chickenpox. After an initial outbreak of chickenpox (often during childhood), the virus remains inactive within the nerve cells of the central nervous system. But in some people, the varicella-zoster virus will reactivate at another time in their lives. When this occurs, the virus travels down long nerve fibers and infects some part of the body, producing a blistering rash (shingles), fever, painful inflammations of the affected nerve fibers, and a general feeling of sluggishness. Varicella-zoster virus may travel to the head and neck, perhaps involving an eye, part of the nose, cheek, and forehead. In about 40 percent of those with shingles in these areas, the virus infects the cornea. Doctors will often prescribe oral anti-viral treatment to reduce the risk of the virus infecting cells deep within the tissue, which could inflame and scar the cornea. The disease may also cause decreased corneal sensitivity, meaning that foreign matter, such as eyelashes, in the eye are not felt as keenly. For many, this decreased sensitivity will be permanent.

Although shingles can occur in anyone exposed to the varicella-zoster virus, research has established two general risk factors for the disease: (1) Advanced age; and (2) A weakened immune system. Studies show that people over age 80 have a five times

greater chance of having shingles than adults between the ages of 20 and 40. Unlike herpes simplex I, the varicella-zoster virus does not usually flare up more than once in adults with normally functioning immune systems.

Be aware that corneal problems may arise months after the shingles are gone. For this reason, it is important that people who have had facial shingles schedule follow-up eye examinations.

**Iridocorneal Endothelial Syndrome.** More common in women and usually diagnosed between ages 30-50, iridocorneal endothelial (ICE) syndrome has three main features: (1) Visible changes in the iris, the colored part of the eye that regulates the amount of light entering the eye; (2) Swelling of the cornea; and (3) The development of glaucoma, a disease that can cause severe vision loss when normal fluid inside the eye cannot drain properly. ICE is usually present in only one eye.

ICE syndrome is actually a grouping of three closely linked conditions: iris nevus (or Cogan-Reese) syndrome; Chandler's syndrome; and essential (progressive) iris atrophy (hence the acronym ICE). The most common feature of this group of diseases is the movement of endothelial cells off the cornea onto the iris. This loss of cells from the cornea often leads to corneal swelling, distortion of the iris, and variable degrees of distortion of the pupil, the adjustable opening at the center of the iris that allows varying amounts of light to enter the eye. This cell movement also plugs the fluid outflow channels of the eye, causing glaucoma.

The cause of this disease is unknown. While we do not yet know how to keep ICE syndrome from progressing, the glaucoma associated with the disease can be treated with medication, and a corneal transplant can treat the corneal swelling.

**Keratoconus.** This disorder--a progressive thinning of the cornea--is the most common corneal dystrophy in the U.S., affecting one in every 2000 Americans. It is more prevalent in teenagers and adults in their 20s. Keratoconus arises when the middle of

the cornea thins and gradually bulges outward, forming a rounded cone shape. This abnormal curvature changes the cornea's refractive power, producing moderate to severe distortion (astigmatism) and blurriness (nearsightedness) of vision. Keratoconus may also cause swelling and a sight-impairing scarring of the tissue.

Studies indicate that keratoconus stems from one of several possible causes:

- An inherited corneal abnormality. About seven percent of those with the condition have a family history of keratoconus.
- An eye injury, i.e., excessive eye rubbing or wearing hard contact lenses for many years.
- Certain eye diseases, such as retinitis pigmentosa, retinopathy of prematurity, and vernal keratoconjunctivitis.
- Systemic diseases, such as Leber's congenital amaurosis, Ehlers-Danlos syndrome, Down syndrome, and osteogenesis imperfecta.

Keratoconus usually affects both eyes. At first, people can correct their vision with eyeglasses. But as the astigmatism worsens, they must rely on specially fitted contact lenses to reduce the distortion and provide better vision. Although finding a comfortable contact lens can be an extremely frustrating and difficult process, it is crucial because a poorly fitting lens could further damage the cornea and make wearing a contact lens intolerable.

In most cases, the cornea will stabilize after a few years without ever causing severe vision problems. But in about 10 to 20 percent of people with keratoconus, the cornea will eventually become too scarred or will not tolerate a contact lens. If either of these problems occur, a corneal transplant may be needed. This operation is successful in more than 90 percent of those with advanced keratoconus. Several studies have also reported that 80 percent or more of these patients have 20/40 vision or better after the operation.

The National Eye Institute is conducting a natural history study--called the Collaborative Longitudinal Evaluation of Keratoconus Study--to identify factors that

influence the severity and progression of keratoconus. These includes:

- **Lattice Dystrophy.** Lattice dystrophy gets its name from an accumulation of amyloid deposits, or abnormal protein fibers, throughout the middle and anterior stroma. During an eye examination, the doctor sees these deposits in the stroma as clear, comma-shaped overlapping dots and branching filaments, creating a lattice effect. Over time, the lattice lines will grow opaque and involve more of the stroma. They will also gradually converge, giving the cornea a cloudiness that may also reduce vision.

In some people, these abnormal protein fibers can accumulate under the cornea's outer layer--the epithelium. This can cause erosion of the epithelium. This condition is known as recurrent epithelial erosion. These erosions alter the cornea's normal curvature, resulting in temporary vision problems; and expose the nerves that line the cornea, causing severe pain. Even the involuntary act of blinking can be painful.

To ease this pain, an eye doctor may prescribe eye drops and ointments to reduce the friction on the eroded cornea. In some cases, an eye patch may be used to immobilize the eyelids. With effective care, these erosions usually heal within three days, although occasional sensations of pain may occur for the next 6 to 8 eight weeks.

By about age 40, some people with lattice dystrophy will have scarring under the epithelium, resulting in a haze on the cornea that can greatly obscure vision. In this case, a corneal transplant may be needed. Although people with lattice dystrophy have an excellent chance for a successful transplant, the disease may also arise in the donor cornea in as little as three years. In one study, about half of the transplant patients with lattice dystrophy had a recurrence of the disease from between two to 26 years after the operation. Of these, 15 percentt required a second corneal transplant. Early lattice and recurrent lattice arising in the donor

cornea responds well to treatment with the excimer laser.

Although lattice dystrophy can occur at any time in life, the condition usually arises in children between the ages of 2 and 7.

- **Map-Dot-Fingerprint Dystrophy.** This dystrophy occurs when the epithelium's basement membrane develops abnormally (the basement membrane serves as the foundation on which the epithelial cells, which absorb nutrients from tears, anchor and organize themselves). When the basement membrane develops abnormally, the epithelial cells cannot properly adhere to it. This, in turn, causes recurrent epithelial erosions, in which the epithelium's outermost layer rises slightly, exposing a small gap between the outermost layer and the rest of the cornea.

Epithelial erosions can be a chronic problem. They may alter the cornea's normal curvature, causing periodic blurred vision. They may also expose the nerve endings that line the tissue, resulting in moderate to severe pain lasting as long as several days. Generally, the pain will be worse on awakening in the morning. Other symptoms include sensitivity to light, excessive tearing, and foreign body sensation in the eye.

**Map-dot-fingerprint dystrophy**, which tends to occur in both eyes, usually affects adults between the ages of 40 and 70, although it can develop earlier in life. Also known as epithelial basement membrane dystrophy, map-dot-fingerprint dystrophy gets its name from the unusual appearance of the cornea during an eye examination. Most often, the affected epithelium will have a map-like appearance, i.e., large, slightly gray outlines that look like a continent on a map. There may also be clusters of opaque dots underneath or close to the map-like patches. Less frequently, the irregular basement membrane will form concentric lines in the central cornea that resemble small fingerprints.

Typically, map-dot-fingerprint dystrophy will flare up occasionally for a few years and then go away on its own, with no lasting loss of vision. Most people

never know that they have map-dot-fingerprint dystrophy, since they do not have any pain or vision loss. However, if treatment is needed, eye doctors will try to control the pain associated with the epithelial erosions. They may patch the eye to immobilize it, or prescribe lubricating eye drops and ointments. With treatment, these erosions usually heal within three days, although periodic flashes of pain may occur for several weeks thereafter. Other treatments include anterior corneal punctures to allow better adherence of cells; corneal scraping to remove eroded areas of the cornea and allow regeneration of healthy epithelial tissue; and use of the excimer laser to remove surface irregularities.

- **Ocular Herpes.** Herpes of the eye, or ocular herpes, is a recurrent viral infection that is caused by the herpes simplex virus and is the most common infectious cause of corneal blindness in the U.S. Previous studies show that once people develop ocular herpes, they have up to a 50 percent chance of having a recurrence. This second flare-up could come weeks or even years after the initial occurrence.

Ocular herpes can produce a painful sore on the eyelid or surface of the eye and cause inflammation of the cornea. Prompt treatment with anti-viral drugs helps to stop the herpes virus from multiplying and destroying epithelial cells.

However, the infection may spread deeper into the cornea and develop into a more severe infection called stromal keratitis, which causes the body's immune system to attack and destroy stromal cells. Stromal keratitis is more difficult to treat than less severe ocular herpes infections. Recurrent episodes of stromal keratitis can cause scarring of the cornea, which can lead to loss of vision and possibly blindness.

Like other herpetic infections, herpes of the eye can be controlled. In one large study, researchers found that recurrence rate of ocular herpes was 10 percent within one year, 23 percent within two years, and 63 percent within 20 years. Some factors believed to be associated with recurrence include fever, stress,

sunlight, and eye injury.

The National Eye Institute supported the Herpetic Eye Disease Study, a group of clinical trials that studied various treatments for severe ocular herpes.

- **Pterygium.** A pterygium is a pinkish, triangular-shaped tissue growth on the cornea. Some pterygia grow slowly throughout a person's life, while others stop growing after a certain point. A pterygium rarely grows so large that it begins to cover the pupil of the eye.

Pterygia are more common in sunny climates and in the 20-40 age group.

Scientists do not know what causes pterygia to develop. However, since people who have pterygia usually have spent a significant time outdoors, many doctors believe ultraviolet (UV) light from the sun may be a factor. In areas where sunlight is strong, wearing protective eyeglasses, sunglasses, and/or hats with brims are suggested. While some studies report a higher prevalence of pterygia in men than in women, this may reflect different rates of exposure to UV light.

- Because a pterygium is visible, many people want to have it removed for cosmetic reasons. It is usually not too noticeable unless it becomes red and swollen from dust or air pollutants. Surgery to remove a pterygium is not recommended unless it affects vision. If a pterygium is surgically removed, it may grow back, particularly if the patient is less than 40 years of age. Lubricants can reduce the redness and provide relief from the chronic irritation.
- **Stevens-Johnson Syndrome.** Stevens-Johnson Syndrome (SJS), also called erythema multiforme major, is a disorder of the skin that can also affect the eyes. SJS is characterized by painful, blistering lesions on the skin and the mucous membranes (the thin, moist tissues that line body cavities) of the mouth, throat, genital region, and eyelids. SJS can cause serious eye problems, such as severe conjunctivitis; iritis, an inflammation inside the eye; corneal blisters and

erosions; and corneal holes. In some cases, the ocular complications from SJS can be disabling and lead to severe vision loss.

Scientists are not certain why SJS develops. The most commonly cited cause of SJS is an adverse allergic drug reaction. Almost any drug--but most particularly sulfa drugs--can cause SJS. The allergic reaction to the drug may not occur until 7-14 days after first using it. SJS can also be preceded by a viral infection, such as herpes or the mumps, and its accompanying fever, sore throat, and sluggishness. Treatment for the eye may include artificial tears, antibiotics, or corticosteroids. About one-third of all patients diagnosed with SJS have recurrences of the disease.

SJS occurs twice as often in men as women, and most cases appear in children and young adults under 30, although it can develop in people at any age

- **Corneal Dystrophies**

A corneal dystrophy is a condition in which one or more parts of the cornea lose their normal clarity due to a buildup of cloudy material. There are over 20 corneal dystrophies that affect all parts of the cornea. These diseases share many traits:

- 1 They are usually inherited.
- 2 They affect the right and left eyes equally.
- 3 They are not caused by outside factors, such as injury or diet.
- 4 Most progress gradually Most usually begin in one of the five corneal layers and may later spread to nearby layers.
- 5 Most do not affect other parts of the body, nor are they related to diseases affecting other parts of the eye or body.
- 6 Most can occur in gradually.
- 7 otherwise totally healthy people, male or female.

Corneal dystrophies affect vision in widely differing ways. Some cause severe visual impairment, while a few cause no vision problems and are discovered during a routine

eye examination. Other dystrophies may cause repeated episodes of pain without leading to permanent loss of vision. Some of the most common corneal dystrophies include Fuchs' dystrophy, keratoconus, lattice dystrophy, and map-dot-fingerprint dystrophy,

### **What is a corneal transplant?**

A corneal transplant involves replacing a diseased or scarred cornea with a new one. When the cornea becomes cloudy, light cannot penetrate the eye to reach the light-sensitive retina. Poor vision or blindness may result.

In corneal transplant surgery, the surgeon removes the central portion of the cloudy cornea and replaces it with a clear cornea, usually donated through an eye bank. A trephine, an instrument like a cookie cutter, is used to remove the cloudy cornea. The surgeon places the new cornea in the opening and sews it with a very fine thread. The thread stays in for months or even years until the eye heals properly (removing the thread is quite simple and can easily be done in an ophthalmologist's office). Following surgery, eye drops to help promote healing will be needed for several months.

Corneal transplants are very common in the United States; about 40,000 are performed each year. The chances of success of this operation have risen dramatically because of technological advances, such as less irritating sutures, or threads, which are often finer than a human hair; and the surgical microscope. Corneal transplantation has restored sight to many, who a generation ago would have been blinded permanently by corneal injury, infection, or inherited corneal disease or degeneration

### **What problems can develop from a corneal transplant?**

Even with a fairly high success rate, some problems can develop, such as rejection of the new cornea. Warning signs for rejection are decreased vision, increased redness of the eye, increased pain, and increased sensitivity to light. If any of these last for more than six hours, you should immediately call your ophthalmologist. Rejection can be successfully treated if medication is administered at the first sign of symptoms.

A study supported by the National Eye Institute (NEI) suggests that matching the blood type, but not tissue type, of the recipient with that of the cornea donor may improve the success rate of corneal transplants in people at high risk for graft failure.

Approximately 20 percent of corneal transplant patients--between 6000-8000 a year--reject their donor corneas. The NEI-supported study, called the Collaborative Corneal Transplantation Study, found that high-risk patients may reduce the likelihood of corneal rejection if their blood types match those of the cornea donors. The study also concluded that intensive steroid treatment after transplant surgery improves the chances for a successful transplant.

### **Alternatives to a corneal transplant**

Phototherapeutic keratectomy (PTK) is one of the latest advances in eye care for the treatment of corneal dystrophies, corneal scars, and certain corneal infections. Only a short time ago, people with these disorders would most likely have needed a corneal transplant. By combining the precision of the excimer laser with the control of a computer, doctors can vaporize microscopically thin layers of diseased corneal tissue and etch away the surface irregularities associated with many corneal dystrophies and scars. Surrounding areas suffer relatively little trauma. New tissue can then grow over the now-smooth surface. Recovery from the procedure takes a matter of days, rather than months as with a transplant. The return of vision can occur rapidly, especially if the cause of the problem is confined to the top layer of the cornea. Studies have shown close to an 85 percent success rate in corneal repair using PTK for well-selected patients

- **The Excimer Laser**

One of the technologies developed to treat corneal disease is the excimer laser. This device emits pulses of ultraviolet light--a laser beam--to etch away surface irregularities of corneal tissue. Because of the laser's precision, damage to healthy, adjoining tissue is reduced or eliminated. The PTK procedure is especially useful for people with inherited disorders, whose scars or other corneal opacities limit vision by

blocking the way images form on the retina. PTK has been approved by the U.S. Food and Drug Administration

- **Current Corneal Research**

Vision research funded by the National Eye Institute (NEI) is leading to progress in understanding and treating corneal disease. For example, scientists are learning how transplanting corneal cells from a patient's healthy eye to the diseased eye can treat certain conditions that previously caused blindness. Vision researchers continue to investigate ways to enhance corneal healing and eliminate the corneal scarring that can threaten sight. Also, understanding how genes produce and maintain a healthy cornea will help in treating corneal disease. Genetic studies in families afflicted with corneal dystrophies have yielded new insight into 13 different corneal dystrophies, including keratoconus. To identify factors that influence the severity and progression of keratoconus, the NEI is conducting a natural history study--called the Collaborative Longitudinal Evaluation of Keratoconus (CLEK) Study--that is following more than 1200 patients with the disease. Scientists are looking for answers to how rapidly their keratoconus will progress, how bad their vision will become, and whether they will need corneal surgery to treat it.

#### **4.0 Conclusion**

This unit has considered common ailments, diseases and disorders of cornea. It is hoped that you will find it instructive in the discharge of your clinical duties at any stage of health care you find yourself. Please note that this instruction does not make you an eye care expert. However, the information is worth sharing as you may be the next and only hope of saving a person from going blind.

#### **5.0 Summary**

In this unit, we have examined cornea's response to injuries and common disease and disorders of cornea.

## **6.0 Tutor Marked Assignment**

Describe the following cornea diseases: Pterygium, Corneal dystrophy and Stevens-Johnson Syndrome (SJS)

## **7.0 References and further readings**

Anatomy, Physiology & Pathology of the Human Eye Campbell and Reece, 2002, *Biology 6th edition*, ed. Benjamin Cummings, San Francisco.

## **UNIT 6: OPTHALMIC PUZZLES**

- 1 Introduction
- 2 Objectives
- 3 Main Content
  - 3.1. Vitrectomy

- 3.2 What happens during Laser treatment?
- 3.3 Vitrectomy and Laser Treatment in treating proliferative retinopathy?
- 3.4 Vision Loss from Diabetic Retinopathy
- 3.5 What can I do to protect my vision?
- 3.6 How do I partner with the eye care professional?
- 4 Conclusion
- 5 Summary
- 6 Tutor marked Assignment
- 7 References and Further readings

### **3.1 What is a vitrectomy?**

If there is a lot of blood in the center of the eye (vitreous gel), the patient needs a vitrectomy to restore his sight. If vitrectomies are to be done in both eyes, they are usually done several weeks apart.

A vitrectomy is performed under either local or general anesthesia. The Eye doctor makes a tiny incision in the eye. Next, a small instrument is used to remove the vitreous gel that is clouded with blood. The vitreous gel is replaced with a salt solution. Because the vitreous gel is mostly water, the patient will notice no change between the salt solution and the original vitreous gel.

She/he will probably be able to return home after the vitrectomy. Some people stay in the hospital overnight. The eye will be red and sensitive. The patient will need to wear an eye patch for a few days or weeks to protect his eye. She/he also will need to use medicated eye drops to protect against infection.

### **3.2 What happens during Laser treatment?**

Both focal and scatter laser treatment are performed in the eye clinic. Before the surgery, the eye doctor will dilate the pupil and apply drops to numb the eye. The area

behind the eye also may be numbed to prevent discomfort.

The lights in the eye theatre will be dim. As the patient sit facing the laser machine, the doctor will hold a special lens to the eye. During the procedure, the patient may see flashes of light. These flashes eventually may create a stinging sensation that can be uncomfortable.

The patient will have to be assisted home after surgery by someone else. The pupil will remain dilated for a few hours and must put on a pair of sunglasses.

### **3.3 Are scatter laser treatment and vitrectomy effective in treating proliferative retinopathy?**

**Answer:** Yes. Both treatments are very effective in reducing vision loss. People with proliferative retinopathy have less than a five percent chance of becoming blind within five years when they get timely and appropriate treatment. Although both treatments have high success rates, they do **not** cure diabetic retinopathy.

Once you have proliferative retinopathy, you always will be at risk for new bleeding. You may need treatment more than once to protect your sight.

### **3.4 What can I do if I already have lost some vision from diabetic retinopathy?**

**Answer:** If you have lost some sight from diabetic retinopathy, ask your eye care professional about low vision services and devices that may help you make the most of your remaining vision. Ask for a referral to a specialist in low vision. Many community organizations and agencies offer information about low vision counseling, training, and other special services for people with visual impairments. A nearby school of medicine or optometry may provide low vision services.

The National Eye Institute (NEI) is conducting and supporting research that seeks better ways to detect, treat, and prevent vision loss in people with diabetes. This

research is conducted through studies in the laboratory and with patients.

For example, researchers are studying drugs that may stop the retina from sending signals to the body to grow new blood vessels. Someday, these drugs may help people control their diabetic retinopathy and reduce the need for laser surgery.

### **3.5 How does Herpes simplex infections affects the Eye**

There are two types of herpes simplex virus. Type 1 virus is the usual cause of cold sores around the mouth, and herpes simplex infection in the eye. Type 2 virus is the usual cause of genital herpes. It rarely causes cold sores or eye infections.

#### **Type 1 herpes simplex infections**

The first time you are infected is called the primary infection. Many people become infected with this virus, often during childhood. (The herpes simplex virus can pass through the moist skin that lines the mouth. It is commonly passed on by close contact such as kisses from a family member who has a cold sore.) In many people the primary infection does not cause any symptoms, although in some cases symptoms do occur.

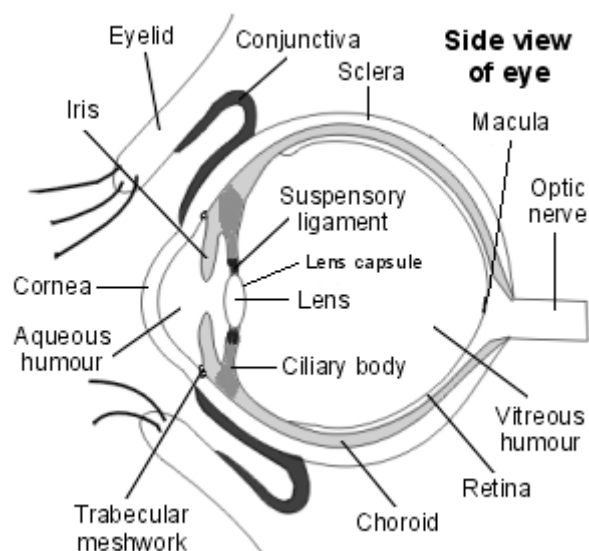
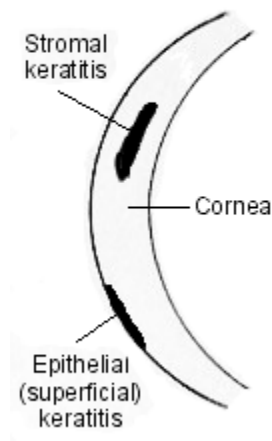
Following the primary infection, the virus stays with you for life. It stays inactive (dormant) in the root of a nerve in the face (the trigeminal nerve).

- In many people, the virus remains permanently inactive and causes no problems.
- In some people, the virus 'activates' and multiplies from time to time. Virus particles then travel down the nerve to cause episodes of active infection with symptoms.
  - In most of these cases, the virus travels down a branch of the nerve to the mouth to cause cold sores. (See separate leaflet called '*Cold Sores*'.)
  - In some of these cases, the virus travels down a branch of the nerve to the eye to cause episodes of active eye infection. The rest of this leaflet is about herpes simplex infection of the eye.

#### **Which part of the eye is affected with herpes simplex infection?**

The common situation is for the cornea to become infected. The cornea is the transparent 'window' of the eye. Infection of the cornea is called keratitis.

**Detail of cornea showing patches of inflammation**



In most cases the infection is just in the top (superficial) layer of the cornea. This is called epithelial keratitis. Sometimes deeper layers of the cornea are involved. This is called stromal keratitis. This is more serious as it is more likely to cause scarring of the cornea.

Other parts of the eye are sometimes affected. A minor and temporary inflammation of

the conjunctiva (conjunctivitis) or eyelids (blepharitis) may occur with active infection, often at the same time as the cornea is infected. Deeper structures such as the retina or iris are sometimes affected.

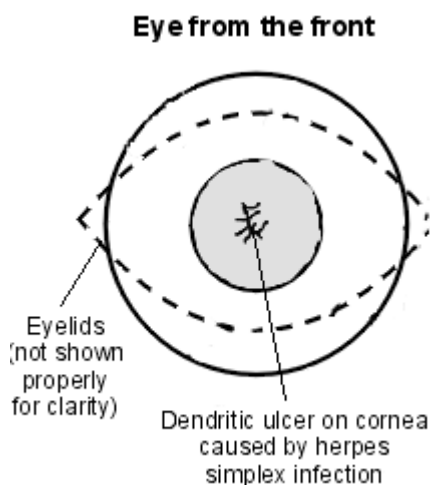
### **Who gets herpes simplex infections of the eye?**

About 1-2 people in 1000 will develop at least one episode of active herpes simplex eye infection at some stage in their life. The most common age for a first episode is aged 30-40.

### **What are the symptoms and signs of active infection?**

Most episodes of active infection are due to a re-activation of the virus at some point, often years after a primary infection. Symptoms include:

- Redness of the eye - mainly around the cornea.
- Ache or pain in the eye.
- Photophobia (discomfort when opening the eyes in bright light).
- Watering of the eye.
- Blurring of vision.



An Eye doctor will usually examine the eye with a magnifier. They may also put some stain on the front of the eye to show up any irregular areas on the cornea. With a herpes simplex infection they will often see a small ulcer (erosion) on the cornea. The typical ulcer which develops is called a 'dendritic' ulcer. Dendritic means 'many fingered'. The ulcer is not round with a smooth edge but like a tree with many finger-like branches.

If you suspects a herpes eye infection in a patient, please refer urgently to an eye specialist. A specialist will do a detailed magnified examination of the eye. This is to confirm the diagnosis and to determine if the infection is in the top layer of the cornea (epithelial keratitis) or if the deeper layers are involved (stromal keratitis).

### **What is the treatment for herpes simplex eye infection?**

#### **If the top (superficial) layer is affected - epithelial keratitis**

Treatment is with antiviral eye ointment or drops (such as acyclovir ointment or ganciclovir drops). These do not kill the virus but stop it from multiplying further until the infection clears. You should take the full course exactly as prescribed. This is often several times a day for up to two weeks. The aim is to prevent damage to the cornea. In some cases, a specialist may also gently scrape the affected part of the cornea to remove affected cells.

#### **If the deeper layer of the cornea is affected - stromal keratitis**

Treatment is similar to epithelial keratitis (above). In addition to the antiviral eye ointment or drops your specialist may add in some steroid eye drops. This helps to reduce inflammation. Note: steroid eye drops must only be used under close supervision of an eye specialist who will prescribe the correct strength and dose in conjunction with antiviral treatment. Used wrongly on their own, steroid drops cause more harm than good.

Antiviral tablets are used in some cases.

#### **If just the eyelids or conjunctiva are affected**

No treatment may be advised. These infections will usually settle on their own in 1-3 weeks. You are likely to be kept under review until the infection goes to check that the cornea does not become infected.

## **Preventing recurring infections**

Some people develop recurring episodes of active infection. As mentioned above, these occur if the virus 'reactivates' from time to time - similar to cold sores. At least half of people who have one episode of active infection will have a recurrence within 10 years of the first. In about 1 in 10 cases, the recurrence is within a year. Recurrences occur more often in some people than others.

If the recurrences are frequent (say, once a year or more) or severe, then your eye specialist may advise that you take antiviral tablets each day to prevent episodes of active infection. Studies have shown that, on average, the number of recurrences is roughly halved in people who take regular antiviral tablets.

Some people say that episodes of active herpes infection may be triggered by strong sunlight. Wearing sunglasses **may** also help to prevent recurrences.

If a recurrence does occur, each episode is treated as described above.

## **What is the outlook (prognosis)?**

The main concern with corneal infection (keratitis) is that it can cause scarring. With scarring the normally clear and transparent cornea become like 'frosted glass'. This can seriously affect vision.

- Epithelial keratitis tends to settle and go away in 1-2 weeks. It has a good outlook and often causes little or no scarring.
- Stromal keratitis is more likely to result in corneal scarring and loss of vision.
- Recurring episodes of active infection can make any existing scarring worse.
- Prompt treatment with antiviral eye ointment or drops helps to minimise damage during each episode of active infection.

Overall, about 9 in 10 'involved eyes' maintain good vision (good enough to drive).

However, severe and recurrent herpes simplex eye infections may lead to serious scarring, impaired vision and even blindness. If blindness develops, a corneal transplant is then the only option to restore vision.

### **3.6 What can I do to protect my vision?**

The NEI urges everyone with diabetes to have a comprehensive dilated eye exam at least once a year. If you have diabetic retinopathy, you may need an eye exam more often. People with proliferative retinopathy can reduce their risk of blindness by 95 percent with timely treatment and appropriate follow-up care.

A major study has shown that better control of blood sugar levels slows the onset and progression of retinopathy. The people with diabetes who kept their blood sugar levels as close to normal as possible also had much less kidney and nerve disease. Better control also reduces the need for sight-saving laser surgery.

This level of blood sugar control may not be best for everyone, including some elderly patients, children under age 13, or people with heart disease. Be sure to ask your doctor if such a control program is right for you.

Other studies have shown that controlling elevated blood pressure and cholesterol can reduce the risk of vision loss. Controlling these will help your overall health as well as help protect your vision.

### **3.7 How do I partner with the eye care professional?**

You can protect yourself against vision loss by working in partnership with your eye care professional. Ask questions and get the information you need to take care of yourself, your family and patients.

#### **What are some questions to ask?**

##### **About my eye disease or disorder...**

- What is my diagnosis?
- What caused my condition?
- Can my condition be treated?

- How will this condition affect my vision now and in the future?
- Should I watch for any particular symptoms and notify you if they occur?
- Should I make any lifestyle changes?

#### **About my treatment...**

- What is the treatment for my condition?
- When will the treatment start and how long will it last?
- What are the benefits of this treatment and how successful is it?
- What are the risks and side effects associated with this treatment?
- Are there foods, drugs, or activities I should avoid while I'm on this treatment?
- If my treatment includes taking medicine, what should I do if I miss a dose?

#### **About my tests...**

- What kinds of tests will I have?
- What can I expect to find out from these tests?
- When will I know the results?
- Do I have to do anything special to prepare for any of the tests?
- Do these tests have any side effects or risks?
- Will I need more tests later?

#### **Other suggestions**

- If you don't understand your eye care professional's responses, ask questions until you do understand.
- Take notes or get a friend or family member to take notes for you. Or, bring a tape recorder to help you remember the discussion.
- Ask your eye care professional to write down his or her instructions to you.
- Ask your eye care professional for printed material about your condition.
- If you still have trouble understanding your eye care professional's answers, ask where you can go for more information.
- Other members of your health care team, such as nurses and pharmacists, can be

good sources of information. Talk to them, too.

Today, patients take an active role in their health care. Be an active health care provider for affordable, available and accessible eye care.

### **Remember...**

If a patient has diabetes, advise to get a comprehensive dilated eye exam **at least once a year**.

- Proliferative retinopathy can develop without symptoms. At this advanced stage, a patient is at high risk for vision loss..
- You can develop both proliferative retinopathy **and** macular oedema and still see fine. However, you are at high risk for vision loss.

The Eye care professional can tell if you have macular edema or any stage of diabetic retinopathy. Whether or not you have symptoms, early detection and timely treatment can prevent vision loss.

## **4.0 Conclusion**

Owing to the delicate nature of the eye, there are millions of puzzles and questions an eye care service recipient will want to ask the provider. That you are not an eye care specialist does not rule this out. And more often than none, no knowledge is a waste as only when one is informed can he/she be able to convince the populace that he truly cares.

## **5.0 Summary**

This unit has considered some basic questions which any patient with the earlier described diseases and disorders may need answers to. These include among others how do I protect my vision and how do I partner with an eye care practitioner.

## **6.0 Tutor Marked Assignment**

1. How will you assist a patient who has diabetes from developing diabetic retinopathy.

## **7.0 References and Further readings.**

Anatomy, Physiology & Pathology of the Human Eye Campbell and Reece, 2002, *Biology 6th edition*, ed. Benjamin Cummings, San Francisco.

<http://www.patient.co.uk/health/Herpes-Simplex-Eye-Infection.htm>..... Accessed 23rd Sept. 2010.

## **UNIT 7: EFFECT OF AGEING ON THE EYE**

- 1 Introduction
- 2 Objectives
- 3 Main Content
  - 3.1. Aging
  - 3.2 Protective features of the Eye
  - 3.3 Vision changes
  - 3.4 Lighting the way: A key to independence
  - 3.5 Anatomical Changes
  - 3.6 Changes in the Eyes Properties
- 4 Conclusion
- 5 Summary

6 Tutor marked Assignment

7 References and Further readings

## **1.0 Introduction**

Everyone's vision deteriorates with age, but there are ways to lessen its impact. This unit will examine various dimensions of aging on the eye.

## **2.0 Objectives**

At the end of this unit, the learner will be able to :

- Explain aging in the context of vision
- Highlight the protective structures of the eye
- Describe the anatomic changes in vision during aging
- Understand the basic eye properties.

## **3.0 Main Content**

### **3.1 Protective features of the Eye**

The eyes are protected in a natural way. They are safely in sockets to stand rough handling. Besides they are extra protected by the lids which can close in a reflex when danger threatens. One winks the lids about ten to fifteen times a minute. In a smoky area, in stress or in concentration it happens even more. The importance of winking is that every time a little tear-water is spread over the eye. Tear-water protects the eyeball from drying and kills damaging bacterium. The whiskers protect the eye against dirt, small insects and sunlight, while the brows protect the eyes from rain or sweat.

### **3.2 Eye and Aging**

The eye converts rays of light into electrical signals. The brains convert these signals and therefore we are able to see. To get a clear image we have to bend the rays of light so that the

join together exactly on the retina in the rear of the eye.

First the rays of light are bent by the surface of the cornea and eventually by the natural lens.

The cornea is the outer layer of the eye. It is transparent and has a spherical shape. The rays of light which enters the eye are bent by the cornea.

The natural lens, which is flexible and can accommodate of shape, is behind the pupil and it converts the fine-tune of the rays. A strong bending of the lens is for instance needed for reading. Between the 40th and 50th year of life the lens will become less flexible and old person's far-sightness starts. Later on, the lens can become turbid and tough. This is a matter of cataract.

In middle age, the lens of the eye becomes less flexible and less able to thicken, and thus less able to focus on nearby objects, a condition called presbyopia. Reading glasses, or bifocal lenses, can help correct this problem.

In old age, changes to the sclera (the white of the eyes) include yellowing or browning due to many years of exposure to ultraviolet light, wind, and dust; random splotches of pigment (more common in people with a dark complexion); and a bluish hue due to increased transparency of the sclera.

The number of mucous cells in the conjunctiva may decrease with age. Tear production may also decrease with age, so that fewer tears are available to keep the surface of the eye moist. Both of these changes explain why older people are more likely to have dry eyes.

Arcus senilis (a deposit of calcium and cholesterol salts) appears as a gray-white ring at the edge of the cornea. It is common in people older than 60. Arcus senilis does not affect vision.

Some diseases of the retina are more likely to occur in old age, including macular degeneration, diabetic retinopathy, and retinal detachment. Other eye diseases, such as cataracts, also become common.

The muscles that squeeze the eyelids shut decrease in strength with age; this, combined with gravity and age-related looseness of the eyelids, sometimes

results in the lower eyelid falling away from the eyeball, a condition called ectropion. In some older people the fat around the orbit shrinks, causing the eyeball to sink into the orbit. Because of lax tissues in the eyelids, the orbital fat can also bulge forward into the eyelids making them appear constantly puffy. The muscles that work to regulate the size of the pupils weaken with age. The pupils become smaller, react more sluggishly to light, and dilate more slowly in the dark. Therefore, people older than 60 may find that objects are not as bright, that they are dazzled initially when going outdoors (or when facing oncoming cars during night driving), and that they have difficulty going from a brightly lit environment to a darker one. These changes may be particularly bothersome when combined with the effects of a cataract.

Other changes in eye function also occur as people age. The sharpness of vision (acuity) is reduced despite use of the best glasses, especially in people who have a cataract, macular degeneration, or advanced glaucoma. The amount of light that reaches the back of the retina is reduced, increasing the need for brighter illumination and for greater contrast between objects and the background. Older people may also see increased numbers of floating black spots (floaters). Floaters usually do not significantly interfere with vision.

As the eye ages certain changes occur that can be attributed to solely the aging process. Most of these anatomic and physiologic processes follow a gradual decline. Although these processes are distinct from the aging eye diseases, the vision changes they produce may be similar, albeit smaller. Physicians and researchers do not usually pay much attention towards understanding these aging related decline in eye functioning, perhaps because of the enormous focus on the effort to understand and treat the blinding aging eye diseases like glaucoma and macular degeneration.

### 3.3 Vision changes

With aging, the quality of vision worsens due to reasons independent of aging eye diseases. While there are many changes of significance in the non-diseased eye, the most functionally important changes seem to be a reduction in pupil size and the loss of accommodation or focusing capability. The area of the pupil governs the amount of light that can reach the retina. The extent to which the pupil dilates also decreases with age. Because of the smaller pupil size, older eyes receive much less light at the retina. The light adapted eye of a 20 year old receives six times more light than that of an 80 year old. In dark adapted conditions, the 20 year old eye receives about 16 times more light. In comparison to younger people, it is as though older persons were wearing medium-density sunglasses in bright light and extremely dark glasses in dim light.

To maximize the light entering the eye, make sure that your eye glasses have anti-reflective coating. Anti-reflective lens coatings significantly reduce surface reflectance and allow greater light transmission through the lens. For CR-39 lenses, approximately 8% of transmitted light is lost to reflectance on the lens surfaces – 4% on the front surface, and 4% on the back surface. Only about 92% of light entering the lens is transmitted to the lens wearer's eyes. A high index material with a refractive index of 1.6 is transmitting only about 90% of incident light, with 10% lost to reflectance. However, when AR coating is applied to both the front and back surfaces of a lens, the percentage of transmitted light for both CR-39 and high index lenses increases to approximately 99%.

For any detailed visually guided tasks on which performance varies with illumination, **older person requires extra lighting**. Aging causes a dramatic slowing in dark adaptation that can be attributed to delayed rhodopsin regeneration in the retinal photoreceptors. This age related delay in dark

adaptation may also contribute to night vision problems commonly experienced by the elderly.

Colour vision and contrast sensitivity are also affected by aging. Colour vision changes cause some reduction of ability to discriminate blues and blue-greens. The yellowing of the lens is believed to be responsible for this effect. The aging lens and cornea causes glare by light scattering, especially for shorter wavelengths. Stray light and lenticular fluorescence washes out contrast.

Wavefront aberrations of the cornea also increase with age, leading to poor vision quality especially when the pupil dilates as in the dark.

The most aggravating aspect of vision in an older person seems to be the feeling that it does not work as effortlessly or as quickly as it did in younger days. They must concentrate harder and require higher levels of illumination than they formerly did in order to have the same perceptual results. Although plain seeing in simplified situations, as in routine vision testing, is as good and as quick as ever, perceiving a complex, changing scene is more difficult and slower. The older person sees parts almost as well as they ever did but organizing of the perception as a whole is more time consuming and require more attention.

**3.4 Lighting the way: A key to independence.** Everyone's vision deteriorates with age, but there are ways to lessen its impact. Good lighting can make the difference between seeing and not seeing for older adults.

Here are some home lighting tips for the elderly:

- **Naked bulbs:** These are worst for older eyes, producing a glare that can be disorienting and painful. Chandeliers are problematic for the same reason.
- **Task lighting:** It makes sense to have a place in the house to do paperwork. Light should be concentrated on the work, not toward the eyes. Adjustable lamps with shades that direct light are recommended. A good choice is a compact fluorescent light with an electronic ballast that

starts up without flickering. Lights should be installed over countertops and stoves.

- **Bathroom lighting:** Lots of light should be provided overhead and even in the shower, where accidents are particularly common. 'Hollywood' lights around the mirror are a poor choice; better is a rectangular fluorescent lamp with an opaque cover to block glare and distribute light upward and outward.
- **Bulb choice:** Be cautious of cheap fluorescent bulbs. Look for phrases such as "high color" or "excellent color rendering," since older eyes often have difficulty defining colors. An 80 or above 'cri' (color rendering index) is recommended. An advantage of fluorescent lighting is its 'blue' energy, which helps older people see colors.

### **3.5 Anatomical changes**

Aging causes laxity and downward shift of eyelid tissues and atrophy of the orbital fat. These changes contribute to the etiology of several eyelid disorders such as ectropion, entropion, dermatochalasis, and ptosis. The higher eyelid skin crease and ptosis may be due to age related disinsertion of the levator muscle aponeurosis, and to involuntional atrophy of the orbital fat. The horizontal eyelid fissure shortens by about 10% with aging

With aging a prominent white ring develops in the periphery of the cornea-called arcus senilis. The number of corneal endothelial cells gradually decrease in number.

The vitreous gel undergoes liquefaction and its opacities - visible as floaters gradually increase in number.

### **3.6 Changes in the Eyes Properties**

Some properties of the eye change roughly linearly with age and present opportunity for non-invasive assessment of age. Three of these properties are:

- Lacrimation

- Fluorescence of the cornea and lens;
- Accommodation.

The first two are objective, whereas the third requires cooperation from the individual. Lacrimation and accommodation decrease with age. Fluorescence of the cornea and lens increase with age. Although specialist equipment and a clear understanding of what one is doing are essential, the tests lend themselves to rapid assessments for incorporation in a set of other age estimates.

#### **4.0 Conclusion**

This unit had examined various dimensions of aging on the eye. Since everyone's vision deteriorates with age, there are ways to lessen its impact. Aging causes laxity and downward shift of eyelid tissues and atrophy of the orbital fat. Good lighting can make the difference between seeing and not seeing for older adults. You are advised to re examine and note these facts so that you can also enjoy good sight even at old age. Remember, the eye is the window of the body

#### **5.0 Summary**

This unit has discussed the effect of aging on the eye. We touched on aging, protective features of the eye, vision changes, lighting the way: a key to independence, anatomical changes and changes in the eyes properties.

#### **6.0 Tutor Marked Assignment**

Describe the changes in the anatomy and eye properties in aging.

#### **7.0 References and further readings**

Anatomy, Physiology & Pathology of the Human Eye Campbell and Reece, 2002, *Biology 6th edition*, ed. Benjamin Cummings, San Francisco.

## **UNIT 8: NON-PENTRATING INJURIES/TRAUMA OF THE EYE**

1.0 Introduction

3.0 Objectives

3.0 Main Content

3.1 Abrasion

3.2 Contusion

3.3 Rupture of the Eye Ball

3.4 Corneal and Conjunctival Foreign Bodies

3.5 Burns

4.0 Conclusion

5.0 Summary

6.0 Tutor Marked Assignment

7.0 Reference

## **1.0 Introduction**

In spite of the protection afforded by the bony orbit, the cushioning effect of the retrobulbar fat, and the lids and lashes – and in spite of the great strides made in recent years in the development of protective devices, especially the use of safety goggles- the incidence of eye injuries remains high. Childhood eye injuries continue to occur as a result of air rifle, bow and arrow, catapult (slingshot), and throwing accidents.

Pain or photophobia caused by the injury may produce blepharospasm severe enough to prevent examination of the eye. If this happens, instill a sterile topical anesthetic. With the aid of a loupe and well-focused light, the anterior surface of the cornea is examined for foreign materials or wounds, regularity, and luster. The conjunctiva is inspected for hemorrhage, foreign material, or tears. The depth and clarity of the anterior chamber are noted, The size, shape, and light reaction of the pupil should be compared with those of the pupil of the uninjured eye. If the eyeball is intact, the lids are carefully inspected to the fornices, everting the upper lid.

It is important to determine and record visual acuity (See NSS 201: Anatomy For Nurses). Visual acuity should be tested again upon recovery from the injury, and a refraction performed if vision is below normal. This record may have legal significance.

In severe injuries it is important for the non-specialist to bear in mind the possibility of causing further damage by unnecessary manipulation. Please note that Topical anesthetics, dyes, and other medications placed in an injured eye must be sterile.

## **2.0 Objectives**

At the end of this unit, the learner is expected to:

- What are non- penetrating injuries of the eyeball
- Describe the signs and symptoms of non-penetrating wounds of the eye

### **3.0 Main Content**

#### **3.1 Non-penetrating injuries of the eyeball : Abrasions**

Abrasions of the lids, cornea, or conjunctiva do not require surgical treatment. The wound should be cleansed of imbedded foreign material. In order to facilitate the examination, the pain associated with abrasions of the cornea and conjunctiva can be relieved by instillation of a topical anesthetic such as 0.5% tetracaine solution, but routine instillation of a topical anesthetic by the patient must not be permitted since it delays normal healing of the epithelium. Ophthalmic antibiotic ointment instilled into the eye lessens the chance of infection. An eye bandage applied with firm but gentle pressure lessens discomfort and promotes healing by preventing movement of the lids over the involved area. The dressing should be changed daily and the wound inspected for evidence of infection or ulcer formation.

Corneal abrasions cause severe pain and may lead to recurrent corneal erosion, but they rarely become infected.

#### **3.2 Contusions**

Contusions of the eyeball and its surrounding tissues are commonly produced by traumatic contact with a blunt object. The results of such injury are variable and are often not obvious upon superficial examination. Careful study and adequate follow-up are indicated. The possible results of contusion injury are hemorrhage and swelling of the eyelids (ecchymosis, "black eye"), subconjunctival hemorrhages, edema or rupture of the cornea, hemorrhage into the anterior chamber (hyphema), rupture of the root of the iris (iridodialysis), traumatic paralysis of the pupil (mydriasis), rupture of the iris sphincter, paralysis or spasm of the muscles of accommodation, anterior chamber angle

recession with subsequent secondary glaucoma, traumatic cataract, dislocation of the lens (subluxation and luxation), vitreous hemorrhage, retinal hemorrhage and retinal oedema (most common in the macular area, called commotion retina, or Berlin's traumatic oedema), detachment of the retina, rupture of the choroid, and optic nerve injury.

Many of these injuries cannot be seen on external observation. Some, such as cataract, may not develop for many days or weeks following the injury.

Except for injuries involving rupture of the eyeball itself, most of the immediate effects of contusion of the eye do not require immediate definitive treatment. However, any injury severe enough to cause intraocular hemorrhage involves the danger of delayed secondary hemorrhage from a damaged uveal vessel, which may cause intractable glaucoma and permanent damage to the eyeball. Patients who show evidence of intraocular hemorrhage should be put at absolute bed rest for 4 or 5 days with both eyes bandaged to minimize the chance of further bleeding. Secondary hemorrhage rarely occurs after 72 hours. A short-acting cycloplegic such as 5% homatropine may be used. Acetazolamide, mannitol, or other systemically administered agents to lower intraocular pressure may be necessary.

### **3.3 Rupture of the Eyeball**

Rupture of the eyeball may occur as a result of penetrating trauma or of contusion which causes a sudden increase in intraocular pressure, causing the wall of the eyeball to tear at one of the weaker points. The most common site of rupture is along the limbus; occasionally, rupture occurs around the optic nerve. Anterior ruptures can be repaired surgically by interrupted sutures unless intraocular contents are so deranged that useful function of the eye is not possible, in which case enucleation is required.

### **3.4 Corneal and Conjunctival Foreign Bodies**

Foreign bodies are the most frequent cause of eye injury. Small metallic or nonmetallic foreign bodies are frequently blown into the eye and may become lodged under the upper lid or be embedded in corneal epithelium. In removing corneal foreign bodies, a sterile topical anesthetic is essential. Minute corneal foreign bodies that are not readily visualized with the naked eye or loupe may be outlined with sterile fluorescein. If a foreign body containing iron has remained in the tissue for any length of time, rust penetrates the corneal tissue and must be removed to prevent further irritation.

Although foreign bodies may often be removed satisfactorily using a light and magnifying loupe, the most satisfactory method is under direct observation with the aid of the greater magnification and illumination of the slitlamp. Although the cornea is very tough, it is also thin (1 mm). Care must be taken not to penetrate the cornea in the process of removing a deeply imbedded foreign body. When in doubt, such deeply placed foreign bodies should be removed in the operating room where the anterior chamber can be re-formed (if necessary) under sterile conditions. Many types of instruments are used for removing superficial corneal foreign bodies, including special blades, and the points of hypodermic needles. A dental drill of the burr type is often useful for removing an imbedded rust ring from the cornea.

Following removal of the foreign body, an antibiotic ointment such as polymyxin B-bacitracin or gentamicin should be instilled 3 times a day into the conjunctival sac to prevent infection. If the wound is extensive, an eye bandage can be used to minimize movement of the lid over the injured area. The wound should be inspected daily for evidence of infection until it is completely healed.

### **3.5 Burns**

Thermal burns of the eye structures are treated as burns of skin structures elsewhere, as the tissues of the lids are most commonly involved. If the damage

has been deep enough to cause sloughing of the corneal tissue, the eye is almost certainly lost by extensive scarring or perforation.

Ultraviolet irradiation, even in moderate doses, often produces a superficial keratitis that is quite painful, although recovery occurs within 12-36 hours without complications. Pain often comes on 6-12 hours after exposure. This type of injury occurs following exposure to an electric welding arc without the protection of a filter. Many “flash burns” are caused by careless exposure in the mistaken belief that the eyes can be burned in this way only when looking directly at the arc. A short circuit in a high-voltage line may cause the same type of injury.

In severe cases of “flash burn,” instillation of a sterile topical anesthetic may be necessary for examination. A mydriatic (eg, homatropine hydrobromide, 2-5%) should be used. Systemic sedation or narcotics are preferable to topical anesthetics, which interfere with corneal healing. Patching and cold compresses are indicated to relieve discomfort.

Infrared exposure rarely produces an ocular reaction. (“Glassblower’s cataract” is rare today but once was common among workers who were required to watch the color changes in molten glass in furnaces without proper filters.) Radiant energy from viewing the sun on an eclipse of the sun without an adequate filter, however, may produce a serious burn of the macula resulting in permanent impairment of vision. Persons using hallucinogenic drugs such as LSD have been particularly prone to solar macular burns.

Excessive exposure to radiation (x-ray) produces cataractorus changes that may not appear for many months after the exposure. The same risk is inherent in exposure to nuclear devices.

#### **4.0 Conclusion**

This unit has discussed various non-penetrating injuries of the eye ball. It is non-penetrating because it does not go beyond outer eye. It has its own consequences, hence appropriate eye health education and carefully watch by parents and guardians is important especially for young people such as school pupils.

## **5.0 Summary**

In this unit, we discussed non-penetrating injuries covering abrasion, contusion, rupture of the eye ball, corneal and conjunctival foreign bodies and burns.

## **6.0 Tutor Marked Assignment**

Differentiate between abrasion and contusion.

## **7.0 References and further readings**

Anatomy, Physiology & Pathology of the Human Eye Campbell and Reece, 2002, *Biology 6th edition*, ed. Benjamin Cummings, San Francisco.

## **UNIT 9: PENETRATING INJURIES/TRAUMA OF THE EYE BALL**

1.0 Introduction

2.0 Objectives

3.0 Main Content

3.1 Lacerations

3.2 Intra-ocular Foreign Bodies

3.3 Injuries to the Lids

3.4 Injuries involving the orbit and its contents

4.0 Conclusion

5.0 Summary

6.0 Tutor Marked Assignment

7.0 Reference

## **1.0 Introduction**

Penetrating injuries affects the middle and inner layer of the eye. The structures includes: the lens, vitreous, and retina which are examined with an ophthalmoscope for evidence of intraocular damage such as hemorrhage or retinal detachment.

If the patient complains of a foreign body sensation but none can be seen with oblique illumination, instill sterile fluorescein. This may demonstrate an irregularity of the corneal surface due to a minute abrasion, laceration, or foreign body.

A small child may be difficult to examine adequately. If a rupture or laceration of the eyeball is suspected, it is best not to struggle but to examine with the aid of a short-acting general anaesthetic. If a severe injury is not suspected, the lids may be manually separated under topical anaesthesia with the use of lid retracting forceps.

This unit will examine few cases of penetrating injuries which occurs day to day. Your understanding and willingness to provide the needed care will help to reduce avoidable blindness.

## **2.0 Objectives**

At the end of this unit, the learners should be able to :

- Describe what penetrating injuries of the eyeball are.
- Distinguish between penetrating and non-penetrating injuries

## **3.0 Main Content**

### **3.1 Lacerations**

Lacerations are usually caused by sharp objects (knives, scissors, a projecting portion of the dashboard of an automobile, etc). Such injuries are treated in different ways depending upon whether or not there is prolapsed of tissue.

### **A. Lacerations Without Prolapse of Tissue.**

If the eyeball has been penetrated anteriorly without evidence of prolapsed of intraocular contents, and if the wound is clean and apparently free from contamination, it can usually be repaired by direct interrupted sutures of fine silk or catgut. Blood clots can be gently removed from the anterior chamber by irrigation and the chamber re-formed after corneal repair by injection of normal saline solution or air. A mydriatic should be used and an antibiotic solution instilled in the conjunctival sac, and bilateral eye bandages applied, The patient should be placed at bed rest for a few days and systemic antibiotics given to minimize the chance of intraocular infection.

**B. Lacerations With Prolapse:** If only a small portion of the iris prolapsed through the wound, this should be grasped with a forceps and excised at the level of the wound lip. Small amounts of uveal tissue can be removed in a similar way. The wound should then be closed in the same manner as a wound without prolapsed, and the same follow-up care given. If uveal tissue has been injured, the possibility of sympathetic ophthalmia is always present.

If the wound has been extensive and loss of intraocular contents has been great enough that the prognosis for useful function is hopeless, evisceration or enucleation is indicated as the primary surgical procedure.

### **3.2 Intraocular Foreign Bodies**

Foreign bodies that have become lodged within the eye should be identified and localized as soon as possible. Particles of iron or copper must be removed to prevent later disorganization of ocular tissues by degenerative changes (siderosis from iron and chalcosis from copper.) Some of the newer alloys are more inert and may be tolerated. Other kinds of particles, such as glass or porcelain, may be tolerated indefinitely and are usually better left alone.

A complaint of discomfort in the eye with blurred vision and a history of striking steel upon steel should arouse a strong suspicion of an intraocular foreign body. The anterior portion of the eye, including the cornea, iris, lens, and sclera, should be inspected with a loupe or slit-lamp in an attempt to localize the wound of entry. Direct ophthalmoscopic visualization of an intraocular foreign body may be possible. An orbital soft tissue x-ray must be taken to verify the presence of a radiopaque foreign body as well as for medico-legal reasons.

Localizing x-rays can be obtained by several methods, usually by the method of Comberg, using a contact lens; or the method of Sweet, with a geometric, calculation following accurate position of the foreign body within the eye or orbit.

The Berman metal locator is an electronic instrument for detecting the presence of metals. It is useful in pinpointing an intraocular foreign body located near one of the accessible areas of the eyeball. The wand of the instrument can be sterilized and passed posteriorly over the exposed field at surgery.

If the foreign body is anterior to the lens annules, it should be removed through an incision into the anterior chamber at the limbus. If it is located behind the lens and anterior to the equator, it should be removed through the area of the parsplana which is nearest to the foreign body because less retinal damage is caused in that manner. If the foreign body is posterior to the equator, it should be removed directly through that point on the wall of the eyeball which is nearest to it, unless that area is at the macula.

If the foreign body has magnetic properties, the sterilized tip of a hand magnet (or giant magnet) near the area of exit can be used to facilitate its removal. If it is non magnetic and removal is essential, small forceps have been devised for introduction into the posterior portion of the eye with minimal displacement and

trauma. A special instrument has been devised to grasp a spherical air rifle or shotgun pellet.

Any damaged area of the retina must be treated with diathermy or photocoagulation to prevent retinal detachment.

### **3.3 Injuries to the lids**

Many lacerations of the lid do not involve the margins and may be sutured in the same way as other lacerations of the skin. If the same way as other lacerations of the skin. If the margin of the lid is involved, however, precautions must be taken to prevent marginal notching. The most effective technique is to freshen the lacerated edges by vertical incisions perpendicular to the lid margins through the full height of the tarsus. The incisions are then joined by a “V”, thus forming a pentagonal wedge. The conjunctiva and tarsus are closed by interrupted gut sutures and the lid margin is carefully aligned with two 7-0 silk sutures: one in the posterior margin through the orifices of the meibomian glands and the other in the anterior lid margin through the lash line. The sutures are allowed to remain about 5 mm long and tied over the skin closure sutures to prevent their abrading the cornea.

If primary repair is not effected within 24 hours, edema may necessitate delayed closure. The wound should be cleansed well and antibiotics administered. After swelling has subsided, repair may be performed. Debridement should be minimized, especially if the skin is not lax.

Lacerations near the inner canthus frequently involve canaliculi. Early repair is desirable, since the tissue becomes more difficult to identify with swelling. The upper canaliculus is rarely essential to lacrimal drainage and can often serve as the sole excretory path when the lower one has been destroyed. Nonetheless, it is preferable to repair such lacerations to prevent stricture. The Veirs rod is an effective canaliculus splint in some cases. The preferred method of repair is an encircling tube of silicone. A pigtail probe is used to identify the lumen of the

severed canaliculus. Silicone tubing is threaded back through the common canaliculus and uninjured punctum. A nylon suture inside the silicone tubing is knotted and the encircling tube rotated to place the knot away from the palpebral opening. Alternatively, the 2 ends of the silicone tubing may be threaded from the 2 puncta with a Quickert probe through the nasolacrimal duct and knotted beneath the inferior turbinate in the nose. These tubes should be left place for several weeks to months. They are easily removed without anesthetic.

### **3.4 Injuries involving the orbit and its contents**

- **Bony Injury**

Fractures of the walls of the orbit may be caused by direct blows or by extension of a fracture line from adjacent bones. The outer table of the frontal bone above the orbit may receive crushing injuries without damaging the orbital contents. Similarly, fractures and displacement of the zygomatic bone, nasal bone and accessory sinuses, and the medial wall of the orbit can be involved in depressed injuries of the face in automobile accidents. If a fracture involves the paranasal sinuses- most frequently the ethmoid bone emphysema may be noted by creptitation on palpation. Such an involvement may be followed by the development of chronic osteomyelitis.

- **Blowout Fracture**

Isolated orbital floor or “blowout” fracture, without concurrent orbital rim fracture, usually follows blunt injury to the eye. Orbital contents herniated into the maxillary sinus, and the inferior rectus or inferior oblique muscle may become incarcerated at the fracture site.

Signs and symptoms are pain and nausea to the time of injury and diplopia on looking up or down. The infraorbital nerve is frequently damaged and anesthesia is noted over the upper lip and gingival Enophthalmos (backward displacement of the eyeball) may not be present until the orbital edema

subsides. The fracture site is best demonstrated by antral roof deformation on Waters' view x-rays or tomograms. There is limited movement of the eye even with forced ductions.

Prompt surgical reduction is indicated when a large bony defect can be demonstrated on radiography or is suspected because of enophthalmos and restricted upgaze. Forced duction is useful in distinguishing the vertical imbalance of entrapment from muscle contusion. If exophthalmoses or restricted motility is not evident, surgical repair is not necessary even if a fracture can be demonstrated. Frequently, a decision cannot be made immediately after injury. There is little danger in waiting 7-10 days to evaluate surgical indications.

### **Two effective means of surgical treatment**

The two effective surgical treatment for penetrating injuries and trauma are Enucleation and Evisceration

### **4.0 Conclusion**

The consequences of penetrating wound can be devastating with untold hardship and stigma. We should do all within our reach to help prevent it through appropriate eye health Education.

### **5.0 Summary**

This unit has discussed penetrating wounds. These includes:lacerations, intra-ocular foreign bodies, injuries to the lids and injuries involving the orbit and its contents.

### **6.0 Tutor Marked Assignment**

Differentiate between laceration with prolapse and laceration without prolapse.

## **7.0 References and Further readings**

Anatomy, Physiology & Pathology of the Human Eye Campbell and Reece, 2002, *Biology 6th edition*, ed. Benjamin Cummings, San Francisco.